

Autism Changes Brain's White Matter over Time

Released: November 23, 2021

At A Glance

- Researchers found significant changes in the microstructure of the brain's white matter in adolescents and young adults with autism spectrum disorder.
- For the study, clinical and DTI data from 583 patients of four distinct patient populations were analyzed: infants, toddlers, adolescents and young adults.
- Impaired connectivity between brain hemispheres was seen in adolescent and young adult ASD patients, but not in infants and toddlers.

CHICAGO — Researchers at Yale University analyzing specialized MRI exams found significant changes in the microstructure of the brain's white matter in adolescents and young adults with autism spectrum disorder (ASD) compared to a control group, according to research being presented next week at the annual meeting of the Radiological Society of North America (RSNA). The changes were most pronounced in the region that facilitates communication between the two hemispheres of the brain.

[download photo](#)



Clara Weber

"One in 68 children in the U.S. is affected by ASD, but high variety in symptom manifestation and severity make it hard to recognize the condition early and monitor treatment response," said Clara Weber, postgraduate research fellow at Yale University School of Medicine. "We aim to find neuroimaging biomarkers that can potentially facilitate diagnosis and therapy planning."

Researchers reviewed diffusion tensor imaging (DTI) brain scans from a large dataset of patients between the age of six months and 50 years. DTI is an MRI technique that measures connectivity in the brain by detecting how water moves along its white matter tracts. Water molecules diffuse differently through the brain, depending on the integrity, architecture and presence of barriers in tissue.

"If you think of gray matter as the computer, white matter is like the cables," Weber said. "DTI helps us assess how connected and intact those cables are."

For the study, clinical and DTI data from 583 patients from four existing studies of distinct patient populations were analyzed: infants—34 with ASD and 121 controls (34% female, median age 7 months); toddlers—57 with ASD and 45 controls (27% female, median age 32 months); adolescents—106 with ASD and 124 controls (49% female, median age 158 months); and young adults—67 with ASD and 29 controls (1% female, median age 230 months).

"One of the strengths of our study is that we looked at a wide range of age groups, not just school-aged children," Weber said.

To assess the influences of age and ASD diagnosis on white matter microstructure, the research team created fractional anisotropy, mean diffusivity and radial diffusivity maps using data from the four studies.

Fractional anisotropy is the extent water diffusion is restricted to just one direction. A value of zero means that diffusion is unrestricted in all directions. A value of one means that diffusion occurs only in one direction. Mean diffusivity is the overall mobility of water molecules, which reflects how densely cells are packed together. Radial diffusivity is the extent water diffuses perpendicular to a white matter tract.

"When white matter integrity is disrupted, we see more water diffusing perpendicularly, which translates to a higher radial diffusivity," Weber said.

The key finding of the analysis was reduced fractional anisotropy within the anterior/middle tracts of the corpus callosum in adolescent and young adult ASD patients compared to individuals in the control group. The corpus callosum is a thick bundle of nerve fibers that connects and allows the two sides of the brain to communicate. Corresponding increases in ASD-related mean diffusivity and radial diffusivity were found in young adults.

"In adolescents, we saw a significant influence of autism," Weber said. "In adults, the effect was even more pronounced. Our results support the idea of impaired brain connectivity in autism, especially in tracts that connect both hemispheres."

No reduction in fractional anisotropy was observed in the same tracts in toddlers and infants with ASD compared to controls.

The researchers hope the findings can help improve early diagnosis of ASD and provide potential objective biomarkers to monitor treatment response.

"We need to find more objective biomarkers for the disorder that can be applied in clinical practice," Weber said.

Co-authors are Robert T. Constable, Ph.D., Sam Payabvash, M.D., Nigel S. Bamford, M.D., Dustin Scheinost, Ph.D., Stefan P. Haider, and Evelyn M.R. Lake, Ph.D.

Note: Copies of RSNA 2021 news releases and electronic images will be available online at [RSNA.org/press21](https://www.rsna.org/press21).

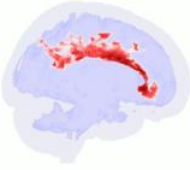RSNA is an association of radiologists, radiation oncologists, medical physicists and related scientists promoting excellence in patient care and health care delivery through education, research and technologic innovation. The Society is based in Oak Brook, Illinois. ([RSNA.org](https://www.rsna.org))

Editor's note: The data in these releases may differ from those in the published abstract and those actually presented at the meeting, as researchers continue

to update their data right up until the meeting. To ensure you are using the most up-to-date information, please call the RSNA Newsroom at 1-312-791-6610.

For patient-friendly information on brain MRI, visit [RadiologyInfo.org](https://radiologyinfo.org).

Video (MP4):



Video 1. Significant alterations in the brain's white matter in adolescents with ASD seen on 3D rendering of fractional anisotropy. [Download](#)

Images (JPG, TIF):

Autism Changes Brain's White Matter over Time

For the study, clinical and DTI data from 583 patients of four existing studies with distinct patient populations were analyzed: infants, toddlers, adolescents and young adults.

Researchers found significant changes in the microstructure of the brain's white matter in adolescents and young adults with autism spectrum disorder.

Impaired connectivity between brain hemispheres was seen in adolescent and young adult ASD patients, but not in infants and toddlers.

RSNA 2021
REDEFINING RADIOLOGY

[RSNA.org/press21](https://rsna.org/press21)

The infographic features three main circular sections. The left section is yellow and contains a magnifying glass icon over a brain diagram. The middle section is maroon and contains four emoji icons representing different age groups: a baby, a toddler, a child, and a young adult. The right section is blue and contains icons of brain hemispheres with connecting lines. The bottom left features the RSNA 2021 logo, and the bottom right contains the website URL.

[High-res \(TIF\) version](#)

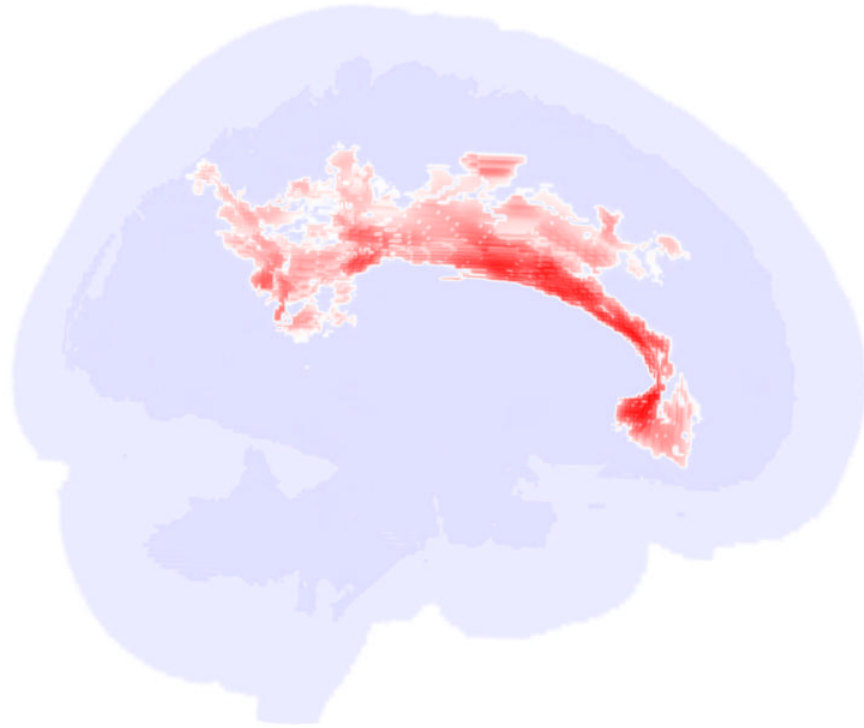
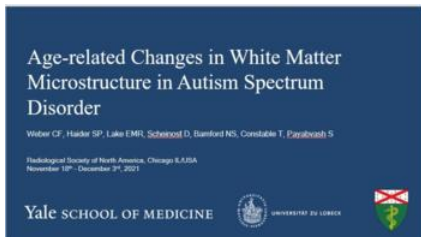

Figure 1. Significant alterations in the brain's white matter in adolescents with ASD.

[High-res. \(TIF\) version](#)

Files:

PowerPoint presentation provided for background reporting purposes only. Do not reprint or reproduce slide content.



[Download](#)

Resources:

[Abstract\(s\).PDF](#)