

RSNA Publishes Fleischner Society Statement on Chest Imaging and COVID-19

Released: April 7, 2020

At A Glance

- The Fleischner Society issued a consensus statement on the role of chest X-ray and CT in COVID-19 diagnosis and management.
- Chest imaging is not indicated for screening or in patients with mild symptoms but is indicated in patients with severe symptoms or worsening respiratory status.
- In a resource-constrained environment, imaging is indicated for medical triage of patients with a high probability of COVID-19.

OAK BROOK, Ill. (April 7, 2020) — A multinational consensus statement from the Fleischner Society on the role of chest imaging in the management of patients with COVID-19 was jointly published today in the journals *Radiology* and *Chest*.

[download photo](#)



Geoffrey D. Rubin, M.D.

“We need to understand that conditions across the globe vary greatly. Our goal in developing this statement was to offer guidance that is sensitive to these differences and applicable broadly,” said Geoffrey D. Rubin, M.D., George B. Geller Professor of Cardiovascular Research, professor of radiology and bioengineering at Duke University School of Medicine in Durham, North Carolina.

The statement represents the collective opinions and perspectives of thoracic radiology, pulmonology, intensive care, emergency medicine, laboratory medicine and infection control experts practicing in 10 countries, representative of the highest burden of COVID-19 worldwide.

“The willingness of experts from around the world to pause from their care of patients to contribute their knowledge and experience toward this international consensus was inspiring,” Dr. Rubin said.

Chest CT and X-ray are key tools in the diagnosis and management of numerous respiratory ailments, but their role in the management of COVID-19 has not been considered within the context of many variables, including the severity of respiratory disease, pre-test probability, risk factors for disease progression, and critical resource constraints.

“The Fleischner statement was uniquely comprised of a multidisciplinary panel comprised principally of radiologists and pulmonologists from 10 countries with experience managing COVID-19 patients across a spectrum of healthcare environments,” said *Radiology* Editor David A. Bluemke, M.D.

The panel evaluated the utility of imaging within three scenarios representing varying risk factors, community conditions and resource constraints.

Fourteen key questions, corresponding to 11 decision points within the three scenarios and three additional clinical situations, were rated by the panel based upon the anticipated value of the information that thoracic imaging would be expected to provide. The results were aggregated, resulting in five main and three additional recommendations intended to guide medical practitioners in the use of chest X-ray and CT in the management of COVID-19.

The results suggested that imaging is not routinely indicated in asymptomatic individuals or patients with suspected COVID-19 and mild clinical symptoms. Use of chest imaging is indicated in patients with COVID-19 who have worsening respiratory status. Imaging is also indicated for patients with moderate to severe features of COVID-19 regardless of COVID-19 test results.

In a resource-constrained environment (lack of personal protection equipment or availability of COVID-19 testing), imaging is indicated for medical triage of patients with suspected COVID-19 who present with moderate to severe clinical features and a high pre-test probability of disease.

The panel also found that CT is appropriate in patients with functional impairment and/or hypoxemia (low level of oxygen in the blood) after recovery from COVID-19. When there is known community transmission, evidence of COVID-19 has been incidentally found on CT scans. In these cases, patients should have COVID-19 testing using a reverse-transcription polymerase chain reaction (RT-PCR) viral assay.

The authors note that this consensus statement represents opinion at a moment in time within a highly dynamic environment where the status of regional epidemics and the availability of critical resources to combat those epidemics vary daily. Recommendations may undergo refinement as the situation evolves.

“Currently, no therapy has been confirmed to alter the course of COVID-19, there is no known cure, and there is no vaccine for prevention,” Dr. Rubin said. “As effective treatments are developed, thoracic imaging may find new roles by establishing treatment response or characterizing patients as likely responders to novel therapies.”

RSNA is committed to connecting radiologists and the radiology community to the most timely and useful COVID-19 information and resources. [RSNA's COVID-19 Resources](#) page houses the latest guidance, original research, image collection and more. The page will be updated on an ongoing basis.

An associated special edition [podcast](#) from Dr. Bluemke is available.

[“The Role of Chest Imaging in Patient Management during the COVID-19 Pandemic: A Multinational Consensus Statement from the Fleischner Society.”](#)

Geoffrey D. Rubin, Christopher J. Ryerson, Linda B. Haramati, Nicola Sverzellati, Jeffrey P. Kanne, Suhail Raoof, Neil W. Schluger, Annalisa Volpi, Jae-Joon Yim, Ian B. K. Martin, Deverick J. Anderson, Christina Kong, Talissa Altes, Andrew Bush, Sujal R. Desai, Jonathan Goldin, Jin Mo Goo, Marc Humbert, Yoshikazu Inoue, Hans-Ulrich Kauczor, Fengming Luo, Peter J. Mazzone, Mathias Prokop, Martine Remy-Jardin, Luca Richeldi, Cornelia M. Schaefer-Prokop, Noriyuki Tomiyama, Athol U. Wells and Ann N. Leung.

Radiology is edited by David A. Bluemke, M.D., Ph.D., University of Wisconsin School of Medicine and Public Health, Madison, Wis., and owned and published by the Radiological Society of North America, Inc. (<http://radiology.rsna.org/>)

RSNA is an association of radiologists, radiation oncologists, medical physicists and related scientists promoting excellence in patient care and health care delivery through education, research and technologic innovation. The Society is based in Oak Brook, Ill. (RSNA.org)

The Fleischner Society is an international, multidisciplinary medical society for thoracic radiology, dedicated to the diagnosis and treatment of diseases of the chest. (Fleischner.memberclicks.net)

For patient-friendly information on chest imaging, visit RadiologyInfo.org.

Images (JPG, TIF):

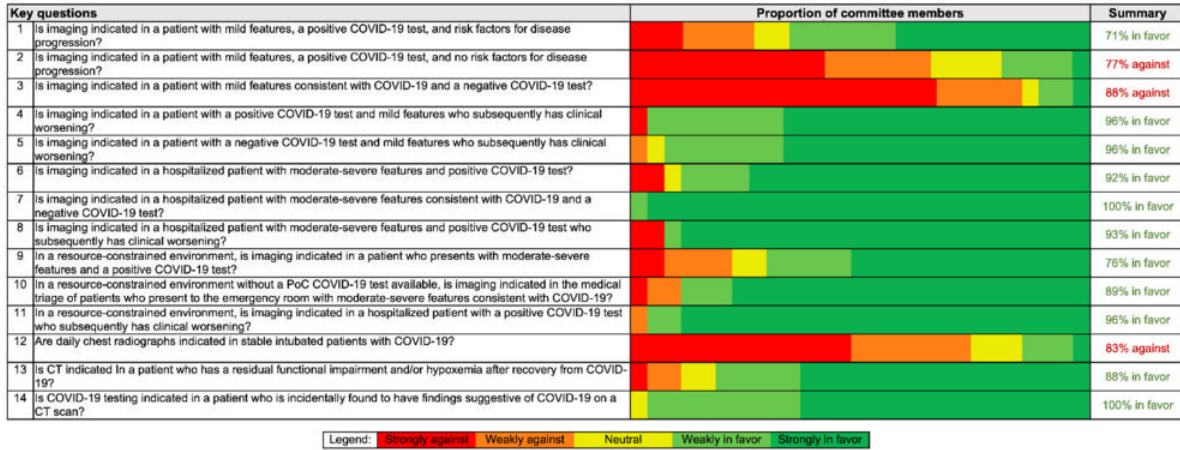


Figure 1. Panel members (total n=27) developed 14 key questions (numerals in left column correspond to question numbers in text and Figures 1-3) that were used to support creation of common scenarios and recommendations related to the use of chest imaging in patients with features of COVID-19. The proportion of panel member votes for each question is presented on a 5-point scale, as well as a summary column that shows the total percentage who voted for or against imaging for each key question, excluding those members who were neutral or who abstained (1 panel member abstained for questions 1 and 2).

[High-res. \(TIF\) version](#)

Resources:

[Study abstract](#)