

Study Suggests Breast Density Alone Not a Risk Factor for Cancer

Released: December 2, 2015

At A Glance

- Contrary to recent reports, a new study found that high breast density was not a strong independent risk factor for breast cancer.
- Researchers looked at data from 52,962 mammography exams performed in women ages 50 to 69 over five years.
- Of 230 detected breast cancers, almost half were from the group with the lowest category of breast density, while slightly less than 3 percent came from women in the highest breast density category.

CHICAGO — Breast density may not be a strong independent factor for breast cancer risk, according to a new study presented today at the annual meeting of the Radiological Society of North America (RSNA).

Prior research has shown an association between breast density and breast cancer. In addition, cancers in dense breast tissue are more difficult to see on mammograms. As a result, some women with dense breasts are advised to get supplementary screening with ultrasound or MRI. Some U.S. states have enacted legislation mandating breast density reporting to women undergoing mammography.

[download full-size photo](#)



Natasa Katavic, M.D.

"In our study, we found that there was no significant difference in breast density between breast cancer patients and the control group in the screening program," said Natasa Katavic, M.D., from the Department of Radiology at Health Center Osijek in Osijek, Croatia.

For the study, Dr. Katavic and colleagues looked at data from 52,962 mammography exams performed in women ages 50 to 69 over five years at five different mammography facilities. Women in Croatia in this age group are invited every two years for mammography by the country's Institute of Public Health.

"We wanted to find out if breast cancer patients had more dense breast tissue than the healthy women," Dr. Katavic said. "Also, we wanted to see what the percentage of dense breasts was in our postmenopausal population and, consequently, determine the value of mammography screening for this group."

Two radiologists read the mammograms independently and determined breast density according to standard criteria. The researchers compared data between patients in the low-density breast tissue group and the high-density group.

The majority of screened woman had low breast density. Of the 230 detected breast cancers, almost half were from the group with the lowest ranked breast density, while slightly less than 3 percent came from women in the highest breast density category.

When the researchers matched the women who had a detected cancer with control participants of the same age and from the same locales who did not have cancer, they found no significant difference in mammographic density. Women with low mammographic density made up 83 percent of the patients in the breast cancer group, compared with 89 percent in the control group, while high mammographic density was found in 17 percent of the breast cancer patients and 11 percent of women in the control group.

The study did not find a strong association between higher mammographic densities and a higher risk of breast cancer among postmenopausal women, according to Dr. Katavic.

"Our study suggests that breast density alone might not be strong independent risk factor for breast cancer," she said. "In risk assessment, all risk factors should be considered before decisions on additional examinations."

The findings also support mammography as an efficient method for early detection of non-palpable breast cancer,

Dr. Katavic said.

Co-authors on the study are Kristina Bojanic, M.D., Prof. Kristina Kralik, Tibor Santo, M.D., Kristina Vidacic, M.D., Mirta Pacovski, M.D., and Miroslav Sikora, D.M.D.

Note: Copies of RSNA 2015 news releases and electronic images will be available online at RSNA.org/press15 beginning Monday, Nov. 30.

RSNA is an association of more than 54,000 radiologists, radiation oncologists, medical physicists and related scientists, promoting excellence in patient care and health care delivery through education, research and technologic innovation. The Society is based in Oak Brook, Ill. (RSNA.org)

Editor's note: The data in these releases may differ from those in the published abstract and those actually presented at the meeting, as researchers continue to update their data right up until the meeting. To ensure you are using the most up-to-date information, please call the RSNA Newsroom at 1-312-791-6610.

For patient-friendly information on mammography, visit RadiologyInfo.org.

Images (JPG, TIF):

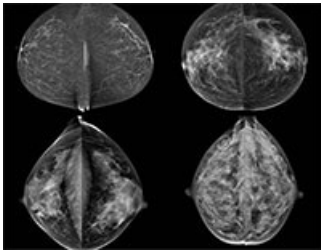


Figure 1. Four different categories of breast density: fatty (top left), scattered fibroglandular (top right), heterogeneously dense (bottom left) and extremely dense (bottom right).

[High-res \(TIF\) version](#)

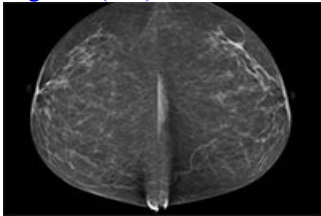


Figure 2. This image shows fatty breast on mammography.

[High-res \(TIF\) version](#)

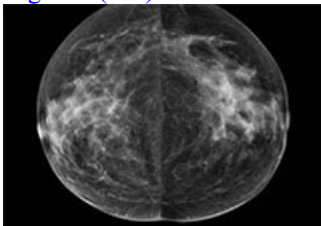


Figure 3. This image shows scattered fibroglandular breast on mammography.

[High-res \(TIF\) version](#)

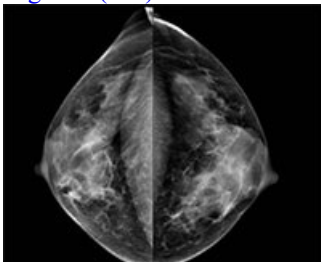


Figure 4. This image shows heterogeneously dense breast on mammography.

[High-res \(TIF\) version](#)

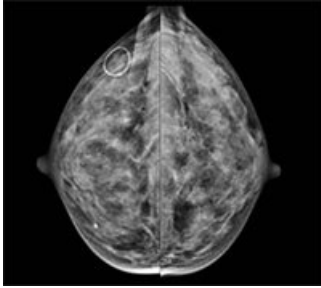


Figure 5. This image shows extremely dense breast on mammography.

[High-res \(TIF\) version](#)

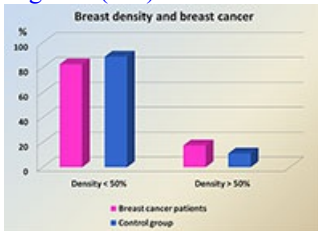


Figure 6.

[High-res \(TIF\) version](#)

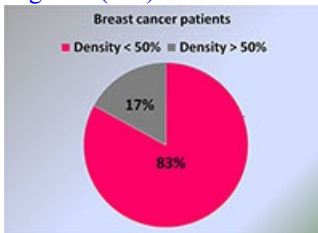


Figure 7.

[High-res \(TIF\) version](#)

Resources:

[Abstract\(s\) PDE](#)