

Creating a Community Standard and Promoting Artificial Intelligence Research in Multiple Sclerosis: A Pre- and Post-Intervention Assessment of the Frequency of Common Data Elements (CDE) Reporting

Andrew S Kuhn, MD; Mike Lee, MD; Ajay Malhotra, MD, MMM; Vahe M Zohrabian, MD; Robert K Fulbright, MD; Ichiro Ikuta, MD, MMedSc

Yale University School of Medicine
Department of Radiology & Biomedical Imaging

Radiological Society of North America 2019 Annual Meeting, Chicago, IL, USA
Thursday, December 5, 2019, 12:45 - 13:15, Room QR Community, Learning Center



WHAT'S A CDE AND WHY DOES IT MATTER?

- A CDE is a standardized reporting term to enhance data quality.
- It is not a template, but can be within one. A template is more general and includes non-disease specific findings.
- A CDE reports granular, disease-specific concepts.

Multiple Sclerosis
CDE

```
Report - UNKNOWN, - MS Cervical Spine
[TEMPORARY]
INDICATION: 25-year-old female, [multiple sclerosis, right upper extremity paresthesias]
TECHNIQUE: Multi-sequential multiplanar MRI cervical spine [both before and after] the IV injection of [3 mL of gadolinium contrast]. [The examination includes Common Data Elements (CDE) reporting for possible multiple sclerosis in the cervical spine]
COMPARISON: [Multiple prior examinations including MRI brain 11/12/2015]
FINDINGS:
CDE Multiple Sclerosis Cervical Spine]
[There are multiple T2-hyperintense lesions] within the [cervical] spinal cord. The [largest lesion] has a craniocaudal span of [3] mm, spanning [less than 1] vertebral body height. This lesion is centered at the C3-C4 level and located within the [central] aspect of the spinal cord, and occupies [less than 50%] of the cross-sectional area of the spinal cord in the axial plane. There [is] no associated spinal cord edema or expansion. The [lesions are] [T1-hypointense] and [do not enhance]. [There are no new lesions]
[The bone marrow signal is within normal limits. There is no bone marrow edema. The vertebral body heights are maintained.] [The cervical lordosis is maintained, without significant spondylolisthesis.] [There is no epidural fluid collection/hematoma.] [The prevertebral and paraspinal soft tissues are unremarkable.] [The visualized portions of the posterior fossa, skull base, and neck soft tissues are grossly unremarkable.]
Atlanto-occipital: [There is normal articulation]
C1-C2: [There is normal articulation. There is no widening of the atlantoaxial distance or rotary subluxation. There is no spinal canal stenosis]
C2-C3: [There is no significant disc herniation, spinal canal stenosis, or neuroforaminal stenosis]
C3-C4: [There is no significant disc herniation, spinal canal stenosis, or neuroforaminal stenosis]
C4-C5: [There is no significant disc herniation, spinal canal stenosis, or neuroforaminal stenosis]
C5-C6: [There is no significant disc herniation, spinal canal stenosis, or neuroforaminal stenosis]
C6-C7: [There is no significant disc herniation, spinal canal stenosis, or neuroforaminal stenosis]
C7-T1: [There is no significant disc herniation, spinal canal stenosis, or neuroforaminal stenosis]
IMPRESSION:
[Multiple T2-hyperintense spinal cord lesions, largest centered at] [C3-C4] [without enhancement]
[No disc herniation or significant spinal canal stenosis]
```

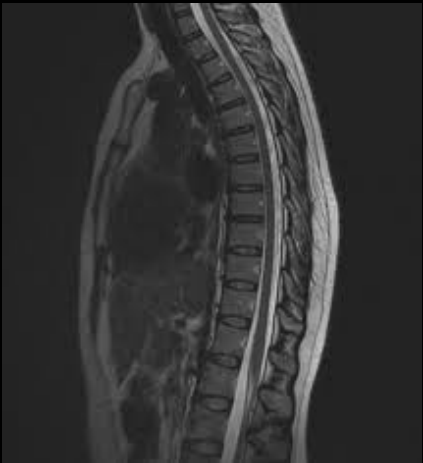Institution Specific Template

Multiple Benefits of CDE's:

- 1) Decreased risk of omitting key findings due to a checklist
- 2) Increased reader clarity due to consistency
- 3) Improved Data Mining for Artificial Intelligence Algorithms

METHODS

- Inclusion criteria: Spine MRI evaluating MS and/ or Demyelinating Disease in the indication
- Exclusion criteria: Degenerative Spine Disease, Osteomyelitis, Metastatic Disease
- Before and after the introduction of CDE templates to the neuroradiology department on 1/1/2019, the PACS was queried for MRI Spine exams



METHODS

- The primary outcome was the change in reporting of CDE fields before and after the formal introduction of the CDE template, along with the percentage of the 11 CDE fields explicitly reported in each report.
- The secondary outcome was the adoption rate of CDE templates (these templates do not automatically populate for each report, and must be inserted when indicated).

ASNR-ACR-RSNA Common Data Elements (CDE) Multiple Sclerosis Spine		
Lesion Number	Lesion Span	Cord Edema
Lesion Location	Cross-Sectional Extent	Cord Expansion
Largest Lesion Identified	T1-Appearance	Cord Expansion Span
Largest Lesion Size	Enhancement	

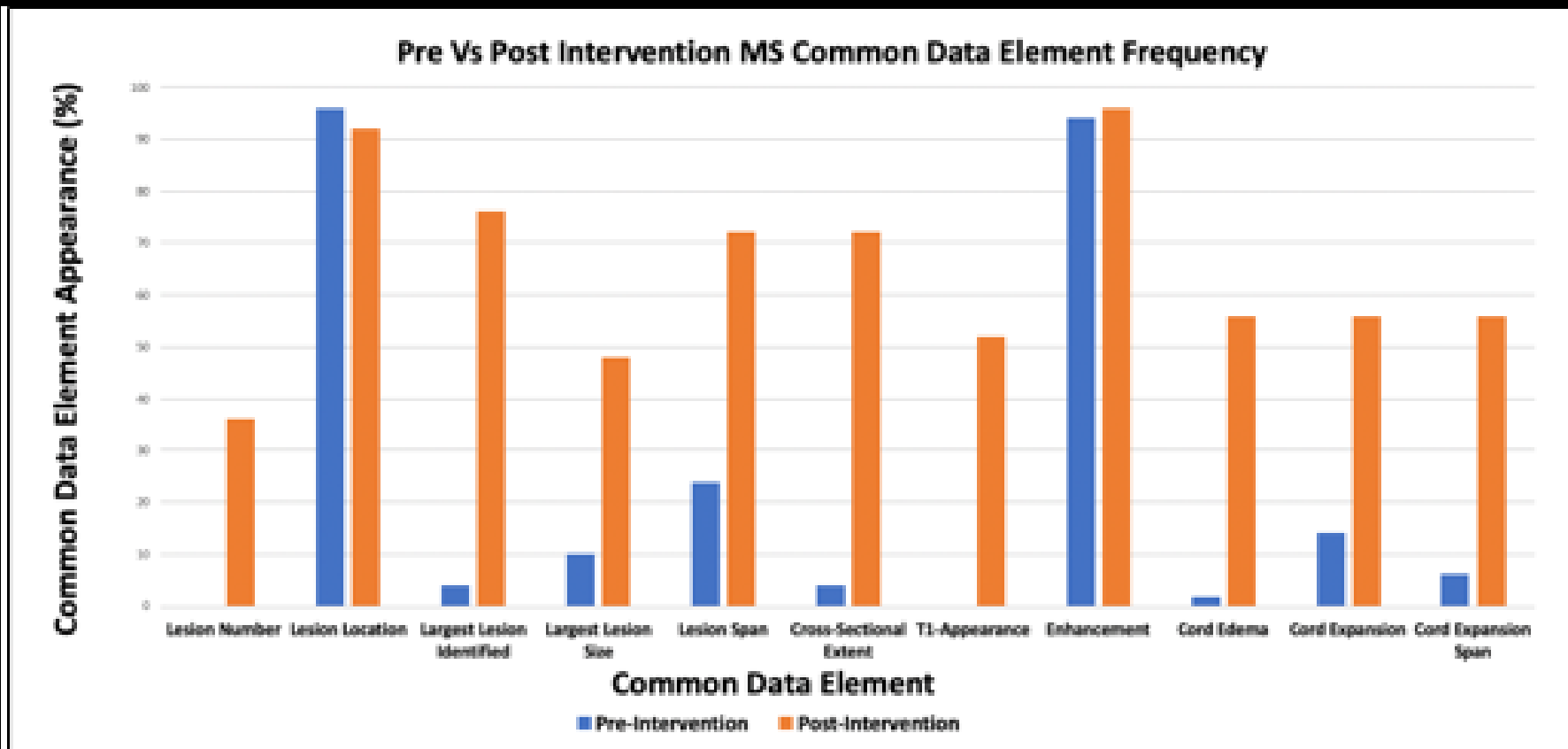


RESULTS

- From the pre-intervention period, the most frequently reported CDE were: cervical or thoracic location (95.9%), enhancement (93.8%), and lesion span (22.4%).
 - Meanwhile, the least consistently reported CDE were: lesion number (0%), T1-appearance (0%), and cord edema (0%).
- From the post-intervention period, the most frequently reported CDE were: enhancement (96%), cervical or thoracic location (92%), and largest lesion identified (76%).
- **Reporting of all of the Common Data Elements increased across all fields following the intervention of introducing formal CDE templates, except in the case of location (96% pre-intervention and 92% post-intervention).**



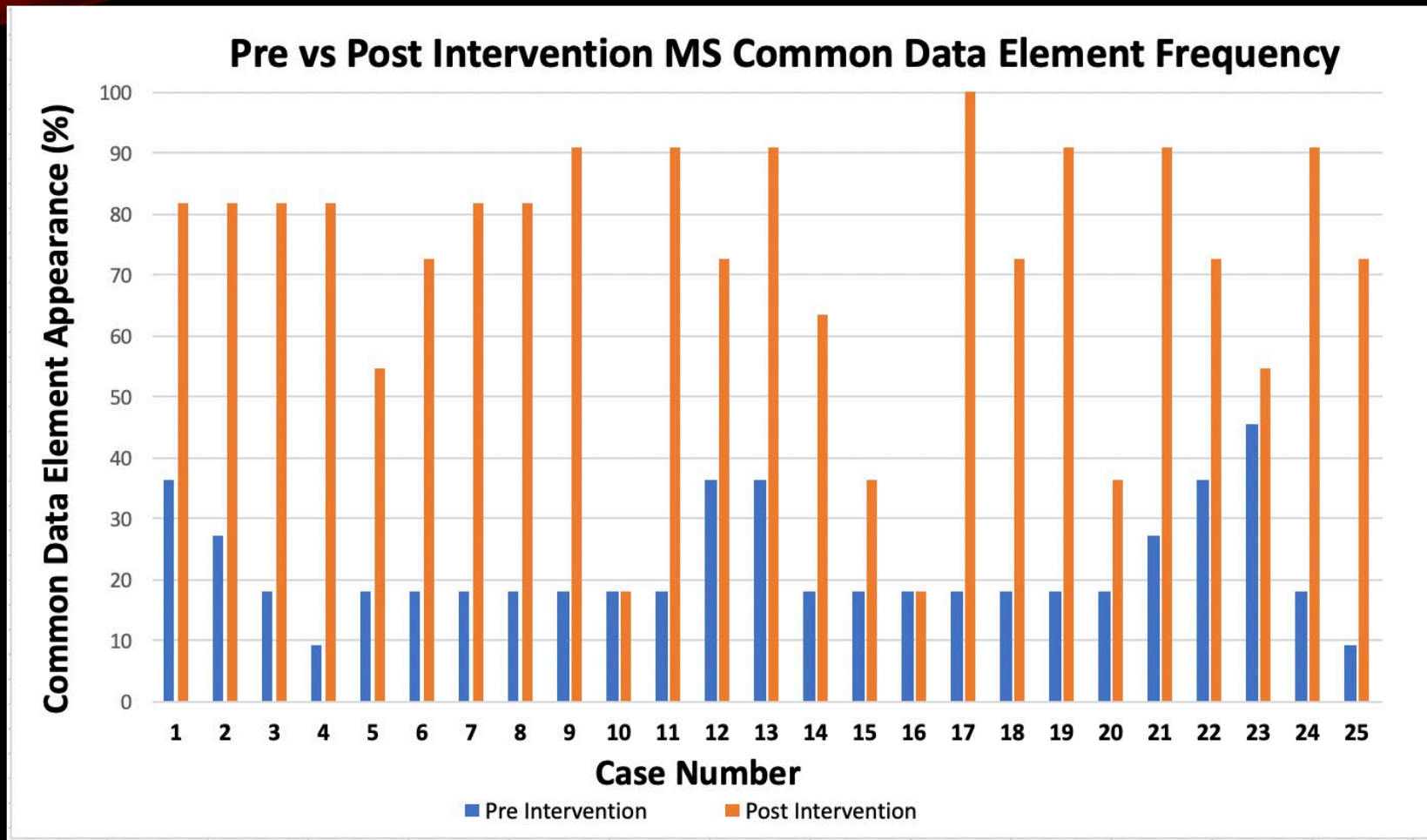
RESULTS



Reporting of all of the Common Data Elements increased across all fields following the intervention of introducing formal CDE templates, except in the case of location (96% pre-intervention and 92% post-intervention).



RESULTS



The case-by-case breakdown in overall percentage of CDE reporting between the pre-intervention and post-intervention cases, showing a demonstrable increase in the percentage of CDE each case reported following intervention.



CONCLUSION

- While the overall core concepts of normal anatomy may be conveyed in reports, major concepts in multiple sclerosis evaluation may not be explicitly reported.
- In addition to hindering quality assurance checks, the use of natural language processing and machine learning is also hindered by the use of broad general statements.
- The RSNA-ASNR-ACR CDE reporting templates provide a starting point for best-practice reporting. Based on the results of this study, a formal introduction of CDE templates into a neuroradiology section leads to a dramatic increase in the frequency by which these disease-specific common data elements are reported.

CONCLUSION

- CDE implementation has a beneficial impact on patient care by increasing the clarity of the reports, decreasing the risk of omitting findings, and leading to improved data curation for research purposes including deep learning algorithms.
- CDE templates also guide trainees' review of pertinent positives/negatives for specific disease entities, holding a great potential educational value.



ACKNOWLEDGEMENTS AND REFERENCES

Thanks to the RSNA, ASNR, ACR, and Yale Radiology & Biomedical Imaging

References:

- 1) Flanders AE, Jordan JE. The ASNR-ACR-RSNA Common Data Elements Project: What Will It Do for the House of Neuroradiology? AJNR Am J Neuroradiol. 2018 Sep 20.
- 2) ASNR 2018 Neuroradiology CDE Distribution Supporting Documentation. <https://www.asnr.org/resources/cde/> Accessed November 5, 2018.
- 3) Rubin DL, Kahn CE. Common data elements in radiology. Radiology 2017;283:837–44.
- 4) Schwartz LH, Panicek DM, Berk AR, et al. Improving communication of diagnostic radiology findings through structured reporting. Radiology 2011;260:174–81.
- 5) Kahn CE Jr., Langlotz CP, Burnside ES, et al. Toward best practices in radiology reporting. Radiology 2009;252:852–56.

