

Assessment Driven Approach to *Integrating Volumetric Software* for **MRI** in **Dementia**

Michelle Pisa, DO | Anirudh Gautam, MD | Oleg Yerstein, MD

Christoph Wald, MD | Mara Kunst, MD



School of
Medicine

Beth Israel Lahey Health 
Lahey Hospital & Medical Center

Objectives

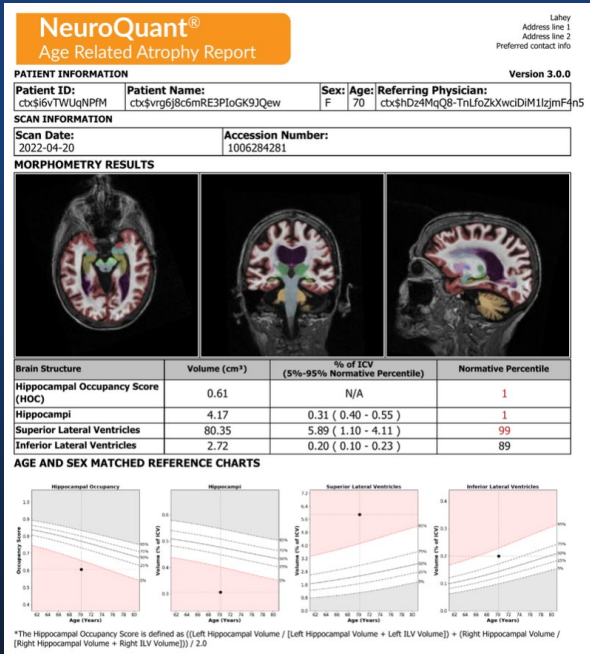
- To **establish a dialogue** regarding the interpretation of dementia imaging in our current practice
- To **review the current literature** on dementia imaging and volumetric software
- To **assess the data** presented from two separate leading vendors in Volumetric MR assessment
- To **establish internal standards** for how to incorporate the volumetric data into our MR interpretation to help guide clinical decision making

Introduction

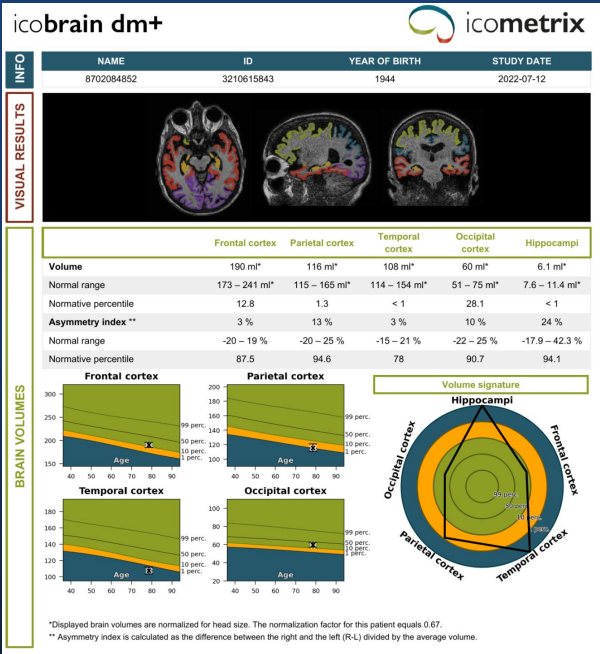
- As the population ages, the overall burden of dementia is increasing worldwide. The most common form of dementia in older adults is Alzheimer's disease (AD), accounting for 60-80% of cases.
- New disease-modifying therapies are available; these require pathological confirmation of abnormal amyloid pathology, usually via PET, which may not be available and/or reimbursed by insurance.
- MRI is routinely ordered for patients with dementia to “rule out” alternate pathologies but can also be used in more of a “rule in” capacity to suggest AD or other types of dementia based on patterns of atrophy.
- Reduced hippocampal volume or medial temporal lobe atrophy is the most characteristic focal finding in AD, in particular, when disproportionate to normal aging.
- Hippocampal volumetry using age-corrected norms can predict rates of progression of mild cognitive impairment (MCI) to dementia.
- Tools to generate these measurements are not in wide use, nor have these findings been validated in a clinical practice setting.

Methods

Volumetric software used



Cortechs.ai
NeuroQuant Dementia



Icometrix
Icobrain dm

- We incorporated the manufacturer-specified imaging sequences into our MRI Dementia protocol
- MRI was interpreted by 1 of 6 fellowship trained / CAQ certified Neuroradiologists without access to any post-processed volumetric data
- Several months later, the radiologists were given the volumetric data, re-reviewed the MRI exam in retrospect, and filled out a questionnaire to assess the impact of this additional data
- 4 participating Neurologists were also asked to review the MRI images and volumetric data and answer questions assessing the impact of the data on their clinical diagnosis and management

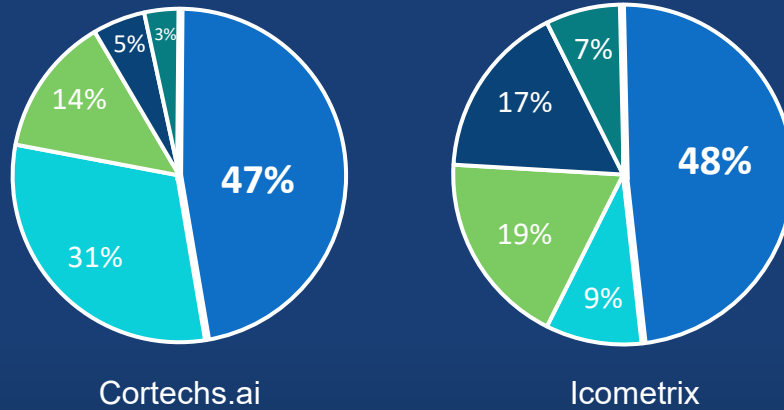
Results

	Neuroquant Radiologists	Icometrix Radiologists	Neuroquant Neurologists	Icometrix Neurologists
Number of responses	59	54	41	32
Does this change your interpretation of the conventional MR images?	Yes, 11/59, 19%, Atrophy, especially hippocampal atrophy	Yes, 9/54, 20%, Atrophy, especially hippocampal atrophy	Yes, 12/41, 29%, Atrophy, especially hippocampal atrophy	Yes, 7/32, 22%, Atrophy, especially hippocampal atrophy
Does this change your diagnosis of the neurodegenerative disorder?	Yes, 4/59, 7%, AD considered more or less likely	Yes, 6/54, 11%, AD considered more or less likely	Yes, 11/41, 27%, AD considered more or less likely	Yes, 11/32, 34%, AD considered more or less likely
Does it help to rule out a diagnosis?	Yes, 5/59, 8%, AD felt to be less likely	Yes, 1/54, 0.02%, AD felt to be less likely	Yes, 15/41, 37%, AD felt to be less likely	Yes, 12/32, 38%, AD felt to be less likely
Does Neuroquantification data change your confidence in the imaging exam?	2/59, 3%, less confidence, 46/59, 78%, no change, 11/59, 19%, more confidence	4/54, 7%, less confidence, 30/54, 56%, no change, 20/54, 37%, more confidence	1/41, 2%, less confidence, 16/41, 39%, no change, 24/41, 59%, more confidence	1/32, 3%, less confidence, 9/32, 28%, no change, 22/32, 69%, more confidence
How would you rate the influence of this additional information on your interpretation of the conventional sequences?	28/59, 47%, no influence, 2/59, 3%, strong influence	26/54, 48%, no influence, 4/54, 7%, strong influence	4/41, 10%, no influence, 9/41, 22%, strong influence	0/32, 0%, no influence, 5/32, 16%, strong influence
How would you rate the influence of this additional information on your clinical interpretation?			4/41, 10%, no influence, 7/41, 17%, strong influence	1/32, 3%, no influence, 3/32, 9%, strong influence
Will this information change clinical management?			Yes, 11/41, 27%	Yes, 11/32, 34%

Results (cont.)

Ratings of influence of the QR on interpretation conventional sequences:

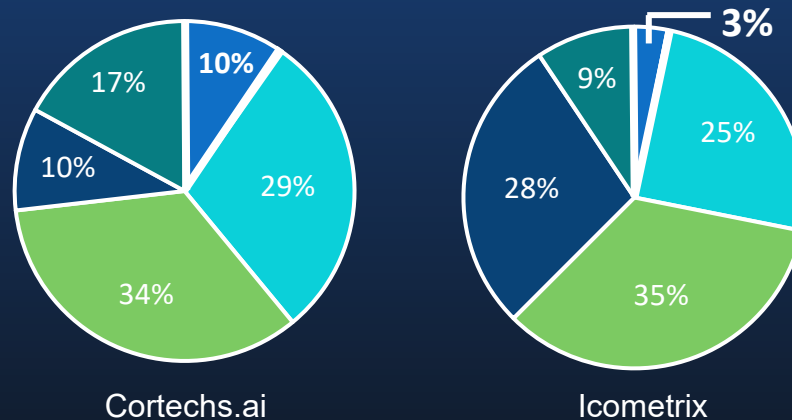
Neuroradiologists



- **Neuroradiologists** felt more comfortable with the conventional images and were less influenced by the data presentation, given known limitations of volumetric data analysis, as well as lack of proven clinical and technical validation

Ratings of influence of the QR on clinical interpretation:

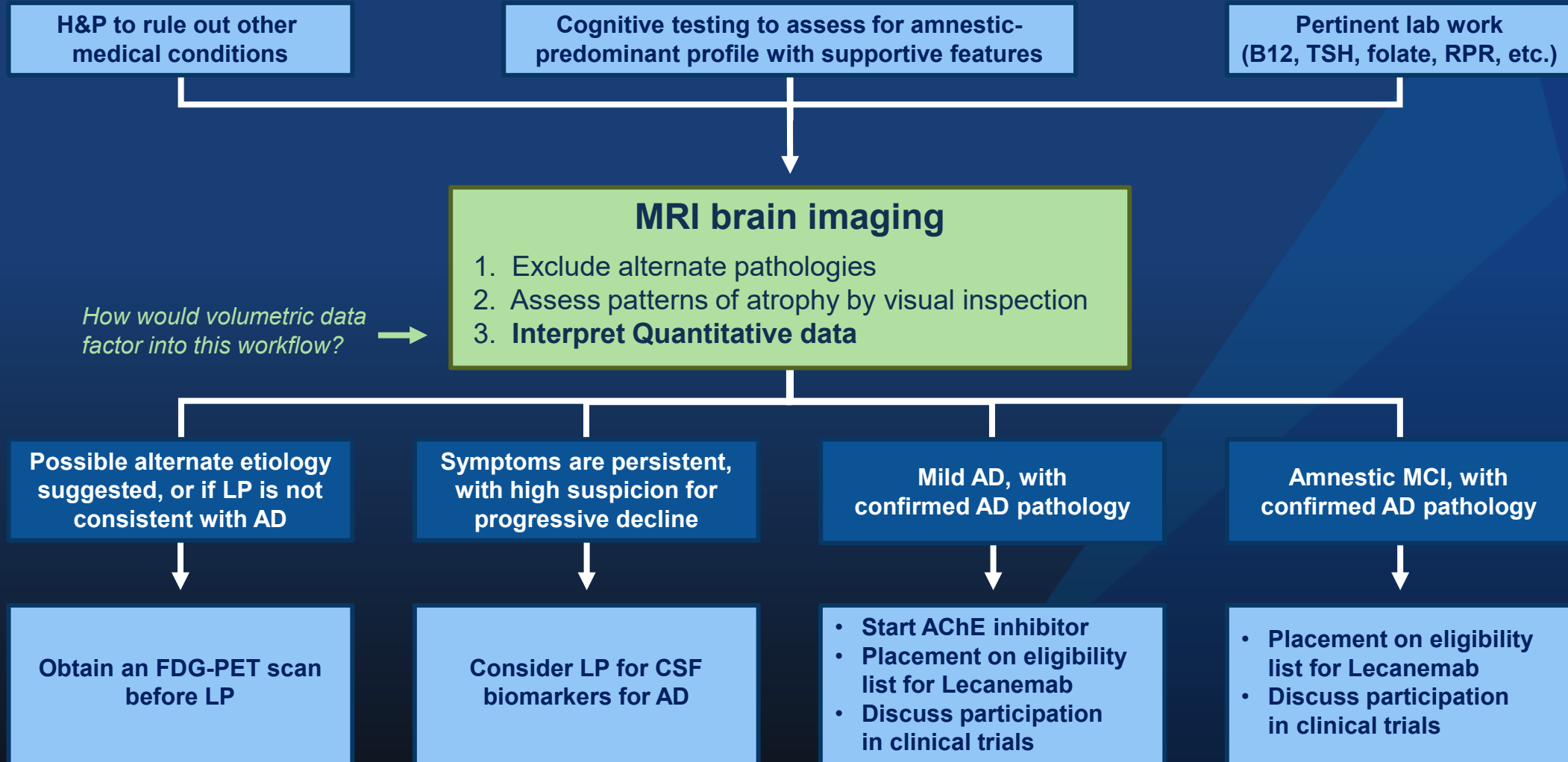
Neurologists



- **Neurologists**, however, indicated a stronger influence of the additional data on their interpretation of the imaging exam and on clinical management



Current Algorithm for Workup of MCI/AD



Discussion

- **What weight is given to the volumetric data?**

The volumetric data is one of several possible indicators of AD, and should not be considered in isolation.

- **What will we consider abnormal hippocampal atrophy? 1 SD or 2 SD?**

Disproportionate hippocampal atrophy 2 standard deviations below the norm would support the diagnosis of AD. Other areas of disproportionate atrophy could indicate an alternate dementia diagnoses.

- **How will radiologists factor the volumetric data into our MRI interpretation?**

The conventional sequences will be reviewed and interpreted independently. The volumetric dataset will be assessed for diagnostic accuracy, noting specific patterns of atrophy, which can be confirmed by retrospective evaluation of the conventional sequences.



EXAM DESCRIPTION: MRI Brain without enhancement

TECHNIQUE: MRI Brain w/o enhancement was performed per [<Protocol>]

COMPARISON: []

INDICATION: []

FINDINGS:

BRAIN/EXTRAAXIAL:

[There is no restricted diffusion to indicate the presence of acute infarction.]

[There is no extra-axial collection, mass effect, or midline shift.]

[No large intracranial hemorrhage is identified.]

[The ventricles, sulci, and cisterns appear proportional and age-appropriate.]

[The major vascular flow voids are preserved.]

BONES/SOFT TISSUES: []

VOLUMETRIC ANALYSIS: [Diagnostic.]

IMPRESSION: []

Conclusion

- We described our approach to end user feedback-based acceptance testing and introduction of volumetric Ai software products into our practice.
- Assessment data was used to gain familiarity with the image appearance and results produced by the products as well as their resonance with the clinical providers.
- In the process we engaged in interdisciplinary dialogue, established interpretation standards, and outlined a clinical workflow, thereby allowing for a more comprehensive purchasing and implementation decision.
- The choice of the preferred solution for permanent production implementation was based on Radiologist preference for spatial resolution in the manufacturer specific source data sequence and Neurologists favoring a more comprehensive data presentation by one vendor.

References

1. American Psychiatric Association. Diagnostic and Statistical Manual of Mental Disorders, Fifth Edition (DSM-5), American Psychiatric Association, 2013.
2. McKhann GM, Knopman DS, Chertkow H, et al. The diagnosis of dementia due to Alzheimer's disease: Recommendations from the National Institute on Aging-Alzheimer's Association workgroups on diagnostic guidelines for Alzheimer's disease. *Alzheimers Dement* 2011; 7:263.
3. Petersen RC. Aducanumab: What about the Patient? *Ann Neurol* 2021; 90:334.
4. Cummings J, Salloway S. Aducanumab: Appropriate use recommendations. *Alzheimers Dement* 2022; 18:531.
5. Jack CR Jr. Alliance for aging research AD biomarkers work group: structural MRI. *Neurobiol Aging*. 2011 Dec;32 Suppl 1(0 1):S48-57. doi: 10.1016/j.neurobiolaging.2011.09.011. PMID: 22078173; PMCID: PMC3661287.
6. Jack CR Jr, Bennett DA, Blennow K, Carrillo MC, Dunn B, Haeberlein SB, Holtzman DM, Jagust W, Jessen F, Karlawish J, Liu E, Molinuevo JL, Montine T, Phelps C, Rankin KP, Rowe CC, Scheltens P, Siemers E, Snyder HM, Sperling R; Contributors. NIA-AA Research Framework: Toward a biological definition of Alzheimer's disease. *Alzheimers Dement*. 2018 Apr;14(4):535-562. doi: 10.1016/j.jalz.2018.02.018. PMID: 29653606; PMCID: PMC5958625.
7. Kuo PH, Zukotynski K. Beyond the AJR: Tau PET, Amyloid PET, and MRI as Prognostic Markers in Early Alzheimer Disease. *AJR Am J Roentgenol*. 2022 May;218(5):924. doi: 10.2214/AJR.21.26836. Epub 2021 Oct 20. PMID: 35234499.
8. Ossenkoppele R, Pichet Binette A, Groot C, Smith R, Strandberg O, Palmqvist S, Stomrud E, Tideman P, Ohlsson T, Jögi J, Johnson K, Sperling R, Dore V, Masters CL, Rowe C, Visser D, van Berckel BNM, van der Flier WM, Baker S, Jagust WJ, Wiste HJ, Petersen RC, Jack CR Jr, Hansson O. Amyloid and tau PET-positive cognitively unimpaired individuals are at high risk for future cognitive decline. *Nat Med*. 2022 Nov;28(11):2381-2387. doi: 10.1038/s41591-022-02049-x. Epub 2022 Nov 10. PMID: 36357681; PMCID: PMC9671808.
9. Whitwell JL, Dickson DW, Murray ME, Weigand SD, Tosakulwong N, Senjem ML, Knopman DS, Boeve BF, Parisi JE, Petersen RC, Jack CR Jr, Josephs KA. Neuroimaging correlates of pathologically defined subtypes of Alzheimer's disease: a case-control study. *Lancet Neurol*. 2012 Oct;11(10):868-77. doi: 10.1016/S1474-4422(12)70200-4. Epub 2012 Sep 3. PMID: 22951070; PMCID: PMC3490201.
10. van de Pol LA, Hensel A, Barkhof F, Gertz HJ, Scheltens P, van der Flier WM. Hippocampal atrophy in Alzheimer disease: age matters. *Neurology*. 2006 Jan 24;66(2):236-8. doi: 10.1212/01.wnl.0000194240.47892.4d. PMID: 16434661.
11. Barkhof F, Polvikoski TM, van Straaten EC, Kalra RN, Sulkava R, Aronen HJ, Niinistö L, Rastas S, Oinas M, Scheltens P, Erkinjuntti T. The significance of medial temporal lobe atrophy: a postmortem MRI study in the very old. *Neurology*. 2007 Oct 9;69(15):1521-7. doi: 10.1212/01.wnl.0000277459.83543.99. PMID: 17923614.
12. Whitwell JL, Josephs KA, Murray ME, Kantarci K, Przybelski SA, Weigand SD, Vemuri P, Senjem ML, Parisi JE, Knopman DS, Boeve BF, Petersen RC, Dickson DW, Jack CR Jr. MRI correlates of neurofibrillary tangle pathology at autopsy: a voxel-based morphometry study. *Neurology*. 2008 Sep 2;71(10):743-9. doi: 10.1212/01.wnl.0000324924.91351.7d. PMID: 18765650; PMCID: PMC2676950.
13. Wahlund LO, Almkvist O, Blennow K, Engedahl K, Johansson A, Waldemar G, Wolf H. Evidence-based evaluation of magnetic resonance imaging as a diagnostic tool in dementia workup. *Top Magn Reson Imaging*. 2005 Dec;16(6):427-37. doi: 10.1097/01.mmr.0000245463.36148.12. PMID: 17088692.
14. Dickerson BC, Wolk DA; Alzheimer's Disease Neuroimaging Initiative. MRI cortical thickness biomarker predicts AD-like CSF and cognitive decline in normal adults. *Neurology*. 2012 Jan 10;78(2):84-90. doi: 10.1212/WNL.0b013e31823efc6c. Epub 2011 Dec 21. PMID: 22189451; PMCID: PMC3466670.
15. McEvoy LK, Holland D, Hagler DJ Jr, Fennema-Notestine C, Brewer JB, Dale AM; Alzheimer's Disease Neuroimaging Initiative. Mild cognitive impairment: baseline and longitudinal structural MR imaging measures improve predictive prognosis. *Radiology*. 2011 Jun;259(3):834-43. doi: 10.1148/radiol.11101975. Epub 2011 Apr 6. PMID: 21471273; PMCID: PMC3099042.
16. Pemberton, H.G., Zaki, L.A.M., Goodkin, O. et al. Technical and clinical validation of commercial automated volumetric MRI tools for dementia diagnosis—a systematic review. *Neuroradiology* 63, 1773–1789 (2021).
17. Goodkin O, Pemberton H, Vos SB et al (2019) The quantitative neuroradiology initiative framework: application to dementia. *Br J Radiol*. <https://doi.org/10.1259/bjr.20190365>.