



Tripler Army Medical Center

Department of Radiology

The Sonographic Murphy Sign: Does Analgesia Matter?

A single center retrospective study demonstrating increased false negative diagnoses (missed acute cholecystitis) after opioid analgesia.

Goldstein, E¹, Marcelo, K¹, Harjes, W², Lustik, M³, Wood, J⁴, Kao, Y¹

¹Dept Radiology, Tripler Army Medical Center, Honolulu, Hawaii, ²Dept Radiology, Joint Base Elmendorf-Richardson Hospital, Anchorage, Alaska, ³Dept Statistics, Tripler Army Medical Center, Honolulu, Hawaii, ⁴Dept Radiology, Washington University, St. Louis, MO

Background

There is an absence of diagnostic radiology based research on the impact of premedication on the sonographic Murphy sign (SMS).

It is estimated that 10-15% of adults in developed countries have gallstones, and gallstone related disease is the most common cause of gastrointestinal related inpatient admissions (1,2). The prevalence of acute cholecystitis in the Western world is 5% with more than 700,000 cholecystectomies performed yearly in the United States (3,4). When a patient presents with right upper quadrant (RUQ) pain, emergency physicians use a combination of patient history, physical examination findings, laboratory tests, and imaging to determine a diagnosis. Unfortunately, no single laboratory test, physical exam or imaging finding can reliably rule in or rule out acute cholecystitis (5). Approximately one-third of patients with suspected acute cholecystitis have a different diagnosis (6).

The right upper quadrant ultrasound (RUQ US) is a sensitive tool to quickly eliminate acute biliary disease in most patients. The sensitivity of ultrasound has been found to be superior to that of CT, 83% vs 39% respectively, with similar specificities, 95% vs 93% respectively (7). Ultrasound findings of acute cholecystitis include gallstones, gallbladder wall thickening, an enlarged gallbladder, pericholecystic fluid, and the SMS. The presence of any one of these findings is not specific for acute cholecystitis, however, the combination of gallstones and a positive SMS has been shown to have a 92% positive predictive value (8).

The SMS is defined as maximal tenderness elicited when the transducer probe is pressed over a sonographically localized gallbladder (9). Unfortunately, the SMS is operator dependent and will likely vary depending on the experience of the sonographer. In addition, controversy exists regarding the diagnostic accuracy of the SMS when patients are given pain control medications prior to their RUQ US. In a recent survey, 100% of emergency radiologists thought opioids administered prior to the assessment of the SMS would have a negative impact. On the contrary, only 10% of emergency medical physicians surveyed thought opioids would have an adverse effect on the SMS (10).

Controversy exists regarding the diagnostic accuracy of the SMS when patients are given pain control medications prior to their ultrasound. Two studies within the last two decades performed by Noble et al. and Nelson et al. concluded there is likely no relationship between opioid analgesia and false positive or false negative SMS (10, 11). Noble et al. reported morphine equivalent doses of 0.5 or 1.0 mg of IV morphine, arguably a non therapeutic dose and Nelson et al. did not report the opioid doses administered to patients (12).

Methods

This study consists of a retrospective cohort chart review to test the null hypothesis: that assessment of the SMS is similar in patients who received and did not receive prior opioid analgesia. The study was conducted at a diagnostic radiology residency program with a Level II, tertiary care emergency department. The attending radiology staff are board-certified or eligible and emergency staff are board-certified. Ultrasound examinations were performed by experienced technologists all of whom had at least 7 years of experience. The research subjects consisted of 686 adult patients who presented to the emergency department with unspecified abdominal pain and had either a RUQ US or gallbladder ultrasound during the study period from January 1, 2018 to September 1, 2019. Twenty-nine (29) of these ultrasound exams were repeat exams from patients who had been previously scanned at least once during the study period for a total of 715 ultrasound exams for 686 individual adult patients. Twenty-three (23) patients scanned had no gallbladder at the time of the exam, 9 patients had no annotation of present or absent sonographic Murphy sign, and 1 patient had pathology done at an outside hospital; these patients were therefore excluded. A total of 682 ultrasound exams were analyzed. Null hypotheses were tested regarding prior opioid analgesia and false positive and false negative radiologic exams, and subdivided by dose and time from dose to scan. The null hypotheses that the sensitivity and specificity of the SMS did not change with prior opioid analgesia versus no prior opioid analgesia was also tested for radiographic diagnosis, emergency department diagnosis, and pathologic diagnosis. The study protocol was approved by the appropriate Human subjects regulatory authority. Investigators adhered to the policies for protection of human subjects as prescribed in 45 Code of Federal Regulation 46.

Statement of Problem

This study addresses the effect of opioid analgesia on the SMS and on final radiologic diagnosis with radiology/pathology concordance or discordance for acute cholecystitis. The study further assesses time elapsed after administration of opioid until scan start time and dose of opioid administered.

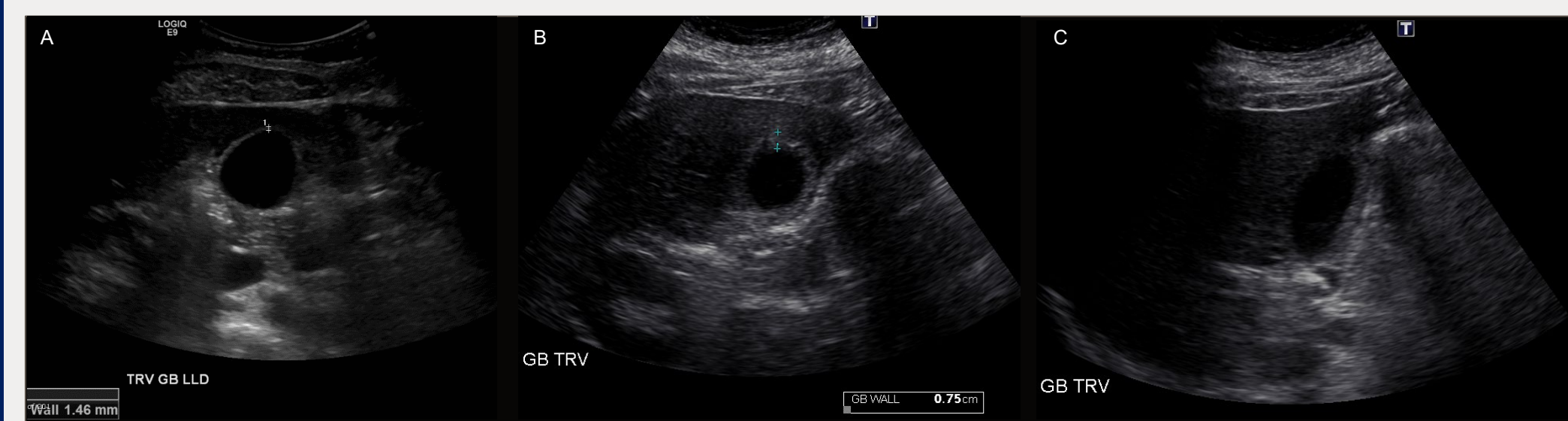


Figure 1. Normal appearance of the gallbladder in transverse, without wall thickening, stones, or pericholecystic fluid (A). Abnormal gallbladder with wall thickening on transverse image (B) and shadowing filling defect representing a gallstone (C).

Setting and Population

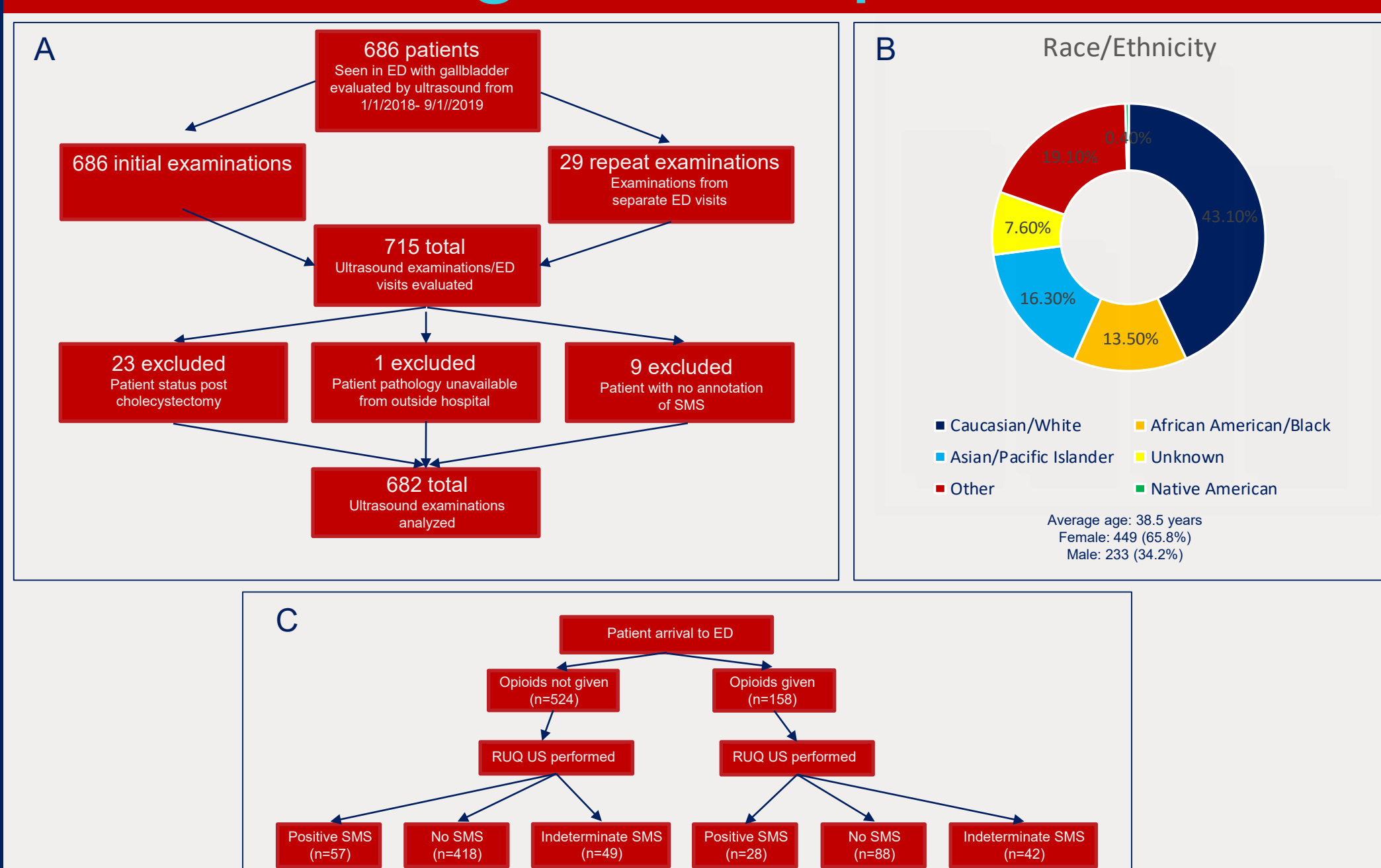


Figure 2. Flow chart of patient selection and exclusion (A). Pie chart of patient race/ethnicity by chart review (B). Flow chart indicating total number of patients who received opioids or did not receive opioids prior to scan, and their SMS result (C).

Equivocal Case Examples

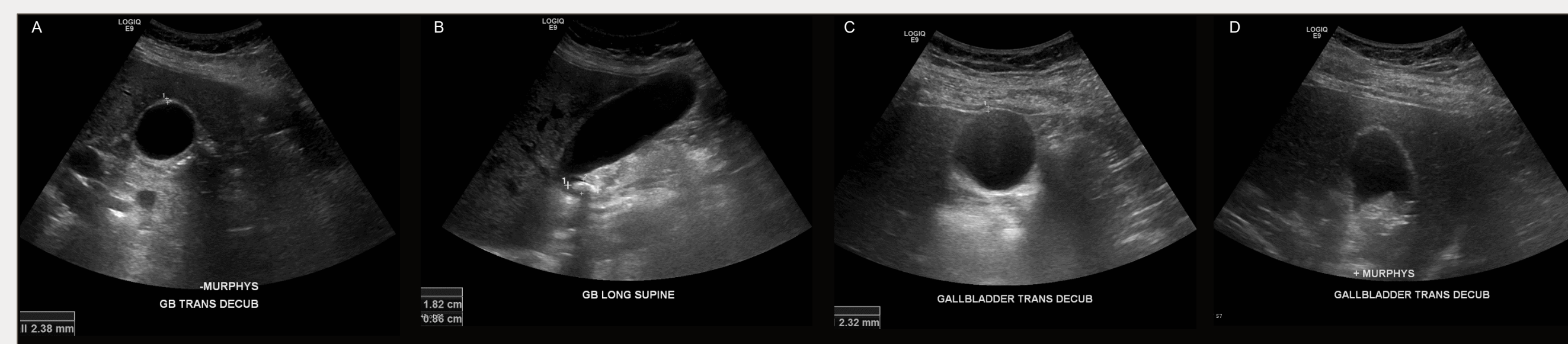


Figure 3. In the case on the left, the patient has normal gallbladder wall thickness and a stone in the gallbladder neck without pericholecystic fluid, or gallbladder wall thickening—and the SMS was not present (A, transverse image; B, long image). Clinical follow up was recommended given the location of the stone; patient did not have an ER diagnosis of acute cholecystitis, and surgery was not pursued. In the case on the right, the patient has normal gallbladder wall thickness and multiple stones/sludge within the gallbladder lumen without pericholecystic fluid, or gallbladder wall thickening—and the SMS was present (C, transverse image; D, long image). This patient was diagnosed with acute cholecystitis, confirmed on pathology.

Outcome Measures

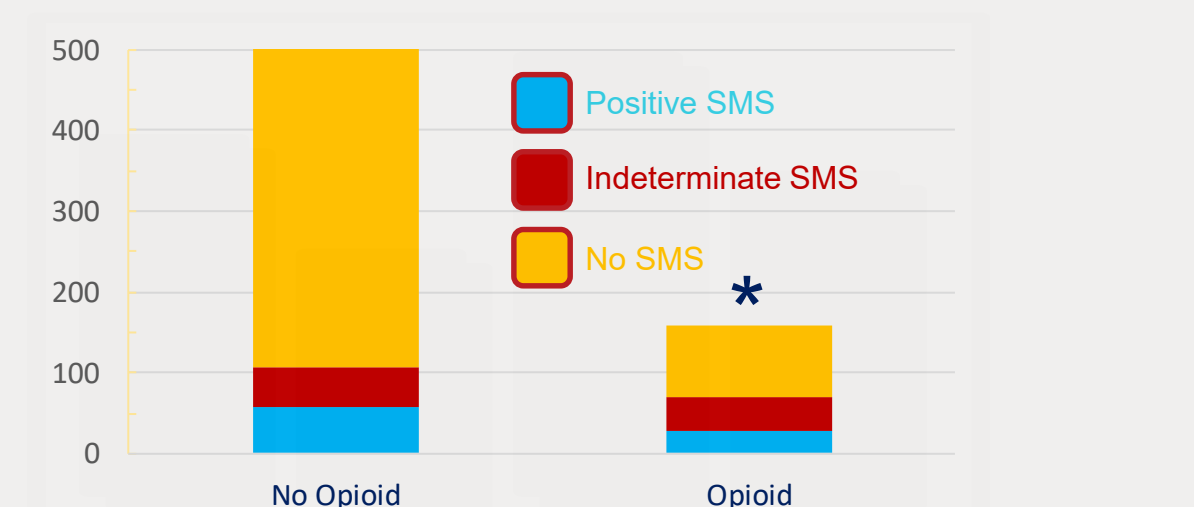


Figure 4. Opioid administration does affect a finding of positive or an indeterminate sonography Murphy sign (p<.0001).

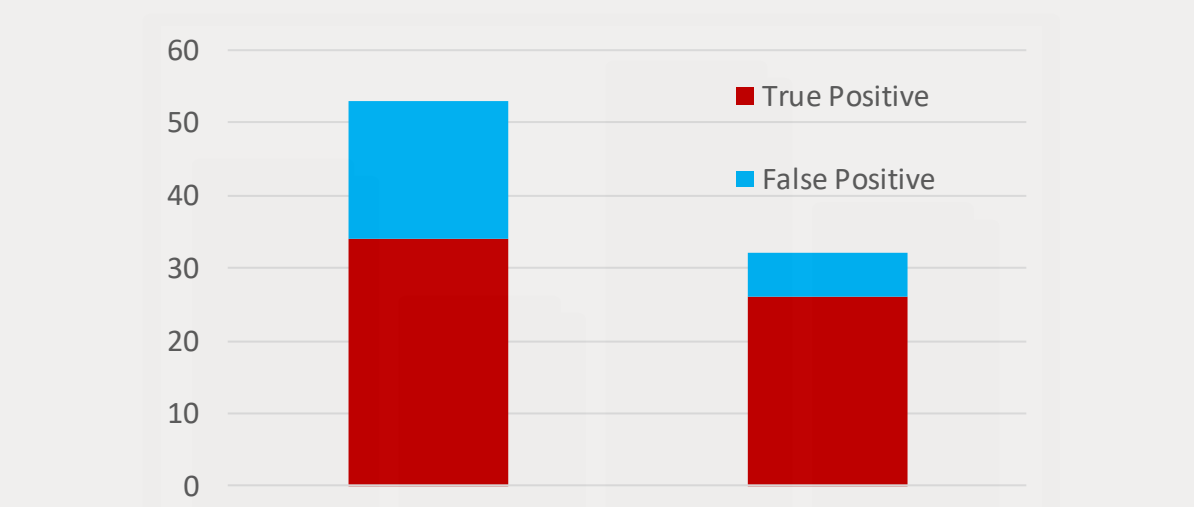


Figure 5. False positive radiologic diagnosis is not significantly affected by opioid administration (p=0.0936). This represents 24 cases of false positive diagnosis of acute cholecystitis.

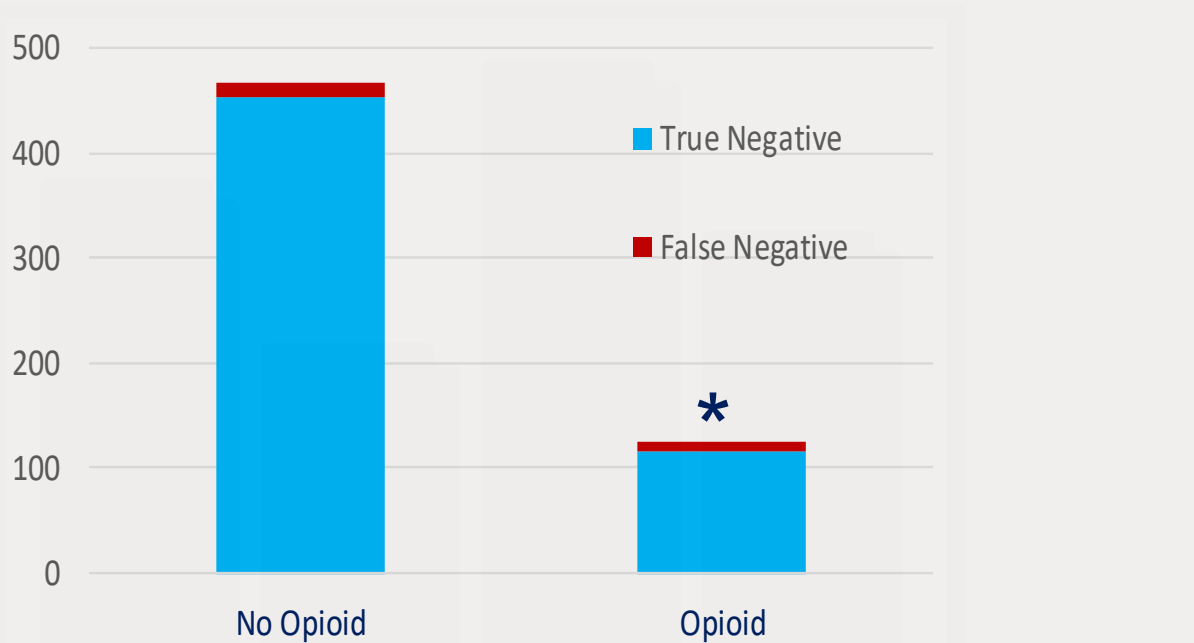


Figure 6. False negative radiologic diagnosis is significantly affected by opioid administration (p=0.0127). This represents 24 cases of radiologic missed acute cholecystitis.

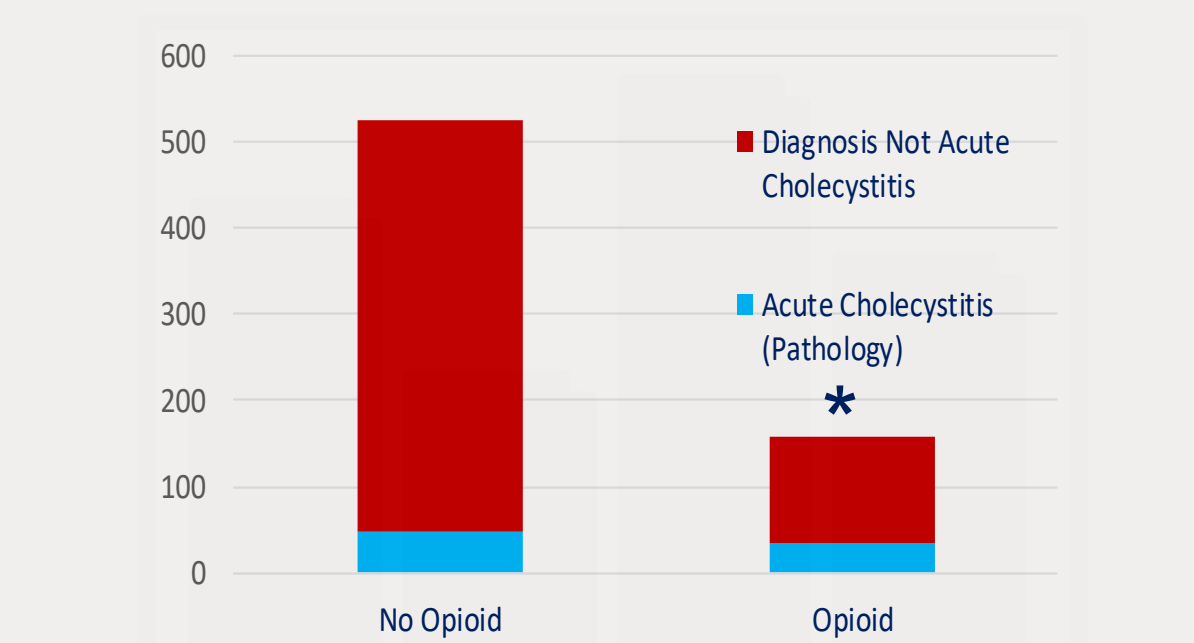


Figure 7. Premedication with opioids prior to ultrasound was significantly associated with a pathologic diagnosis of acute cholecystitis versus other diagnoses (P<.0001).

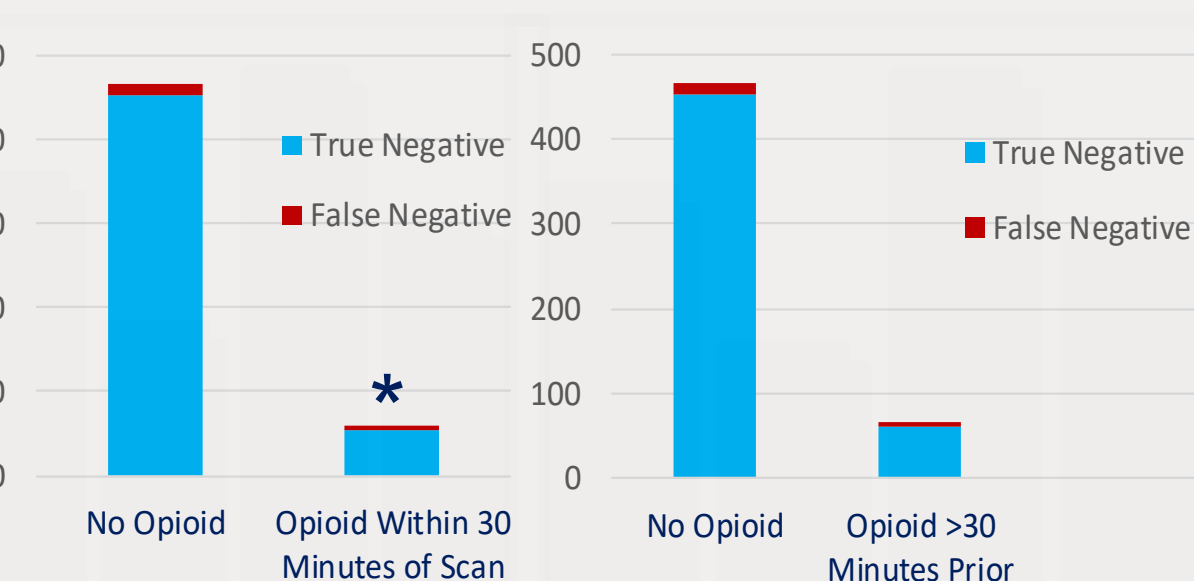


Figure 8. Within the subset of radiologic negative cases, false negative radiologic diagnosis is significantly affected by opioid administration within 30 minutes prior to scan (p=0.034), and is not significantly affected if the scan is more than 30 minutes after opioid premedication (p=0.066).

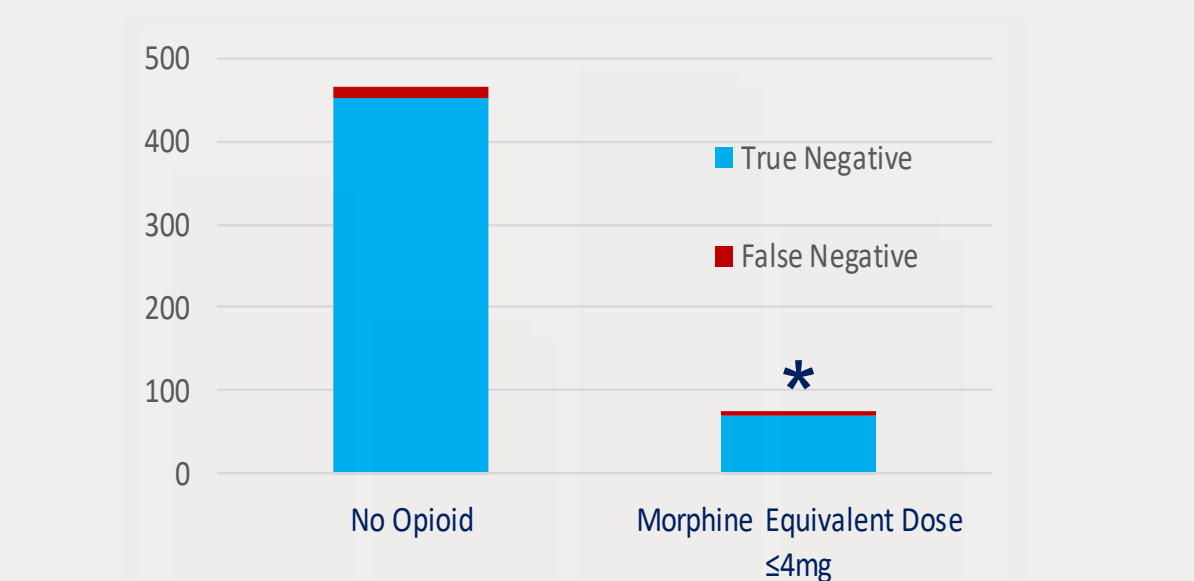


Figure 9. Within the subset of radiologic negative cases, if the morphine equivalent dose administered prior to scan was <=4mg, there is still a statistically significant rate of false negative radiologic diagnoses (p=0.033). This was not further subdivided due to small sample size.

Results

Opioid administration does affect the SMS (p<.001), therefore this null hypothesis is rejected.

Morphine equivalent dose range was 2-24mg with an average dose of 4.9mg IV morphine equivalent. All doses greater than 10mg IV morphine equivalent included multiple doses and/or fentanyl (high conversion factor of 0.1).

Time from opioid dose to ultrasound ranged from 0 to 368 minutes with an average time of 61 minutes from premedication to scan.

False positive radiologic diagnosis is not significantly affected by opioid administration (p=.0936). This represents 24 cases of false positive diagnosis of acute cholecystitis.

False negative radiologic diagnosis is significantly affected by opioid administration (p=.0219). This represents 24 cases of radiologic missed cholecystitis.

Within the subset of negative radiologic results, time from opioid dose to scan of 30 minutes or less is associated with a false negative result (p=0.034) and time from opioid dose to scan of greater than 30 minutes is not associated with a false negative result (p=0.066).

Within the subset of negative radiologic results, dose of opioid prior to scan of less than or equal to IV morphine equivalent dose of 4mg is still associated with a false negative result (p=0.033). No further subdivision of dose was performed due to small sample size.

Patients with a pathologic diagnosis of acute cholecystitis were more likely to have received opioid medication prior to ultrasound (p<.0001).

The sensitivity and specificity of positive SMS are 41.4% and 91.5%, respectively. Therefore opioid analgesia does not affect the sensitivity and specificity of the SMS for pathologic acute cholecystitis (p=.500 and p=.575, respectively).

Opioid analgesia does not affect the sensitivity and specificity of the SMS for radiologic, emergency department, or pathologic acute cholecystitis. There is no significant difference in final diagnosis between radiology and emergency department (p=.736), radiology and pathology (p=.427) and pathology and emergency department (p=.704).

Recommendations

Clinical suspicion must remain higher in patients that have received opioid analgesia prior to ultrasonography with radiographic diagnosis of other than acute cholecystitis.

If ultrasound is anticipated, consider delaying opioid analgesia until completion of the imaging study, given the association with increased false negative studies.

Alternatively, consider delaying ultrasound by 30 minutes if opioid analgesia has been administered.

No dose based recommendations are made.

Discussion

Opioid analgesia prior to ultrasound of the gallbladder or right upper quadrant for acute cholecystitis is associated with a statistically significant increase in false negative results. Premedication with opioids is also correlated with an increased rate of acute cholecystitis.

Despite the association of opioid analgesia prior to scan with false negative radiology results, the sensitivity and specificity of the exam do not demonstrate a statistically significant difference with or without opioid analgesia, and do not significantly differ among the radiologic, emergency department, and pathologic final diagnoses of acute cholecystitis.

Unfortunately, even at a clinically frequent therapeutic dose of 4mg IV morphine equivalent, there is still increased association with false negative radiologic diagnosis, so no dose based recommendations are offered.

References

- Halldestam I, Enell EL, Kullman E, Borch K. Development of symptoms and complications in individuals with asymptomatic gallstones. *British Journal of Surgery* 2004;91(6):734-738.
- Russo MW, Wei JT, Thiny MT, et al. Digestive and liver diseases statistics, 2004. *Gastroenterology* 2004;126(5):1448-1453.
- Stoker J, van Randen A, Laméris W, Boermeester MA. Imaging patients with acute abdominal pain. *Radiology* 2009;253(1):31-46.
- Shaffer EA. Gallstone disease: epidemiology of gallbladder stone disease. *Best Practice & Research: Clinical Gastroenterology* 2006;20(6):981-996.
- Trowbridge RL, Rutkowski NK, Shojania, KG. Does this patient have acute cholecystitis?. *Journal of the American Medical Association* 2003;289(1):80-86.
- Hanbidge AE, Buckler PM, O'Malley ME, et al. From the RSNA refresher courses: imaging evaluation for acute pain in the right upper quadrant. *RadioGraphics* 2004;24(4):1117-1135.
- Harvey RT, Miller WT Jr. Acute biliary disease: initial CT and follow-up US versus initial US and follow-up CT. *Radiology* 1999;213(3):831-836.
- Ralls PW, Colletti PM, Lapin SA, et al. Real-time sonography in suspected acute cholecystitis. Prospective evaluation of primary and secondary signs. *Radiology* 1985;155(3):767-771.
- Bree RL. Further Observations on the Usefulness of the Sonographic Murphy Sign in the Evaluation of Suspected Acute Cholecystitis. *Journal of Clinical Ultrasound* 1995;23:169-172.
- Nelson BP, Senecal EL, Hong C, et al. Opioid analgesia and assessment of the sonographic Murphy sign. *The Journal of Emergency Medicine* 2005;28(4):409-413.
- Noble VE, Lileto AS, Nelson BP, et al. The impact of analgesia on the diagnostic accuracy of the sonographic Murphy's sign. *European Journal of Emergency Medicine* 2010;17:80-83.
- Mariani PJ. Analgesia and the sonographic Murphy's sign. *European Journal of Emergency Medicine* 2010;17(2):127.

Acknowledgements

The views expressed in this publication those of the authors and do not necessarily reflect the official policy of the Department of Defense, Department of the Army, U.S. Army Medical Department, or the U.S. Government

Sensitivity and Specificity

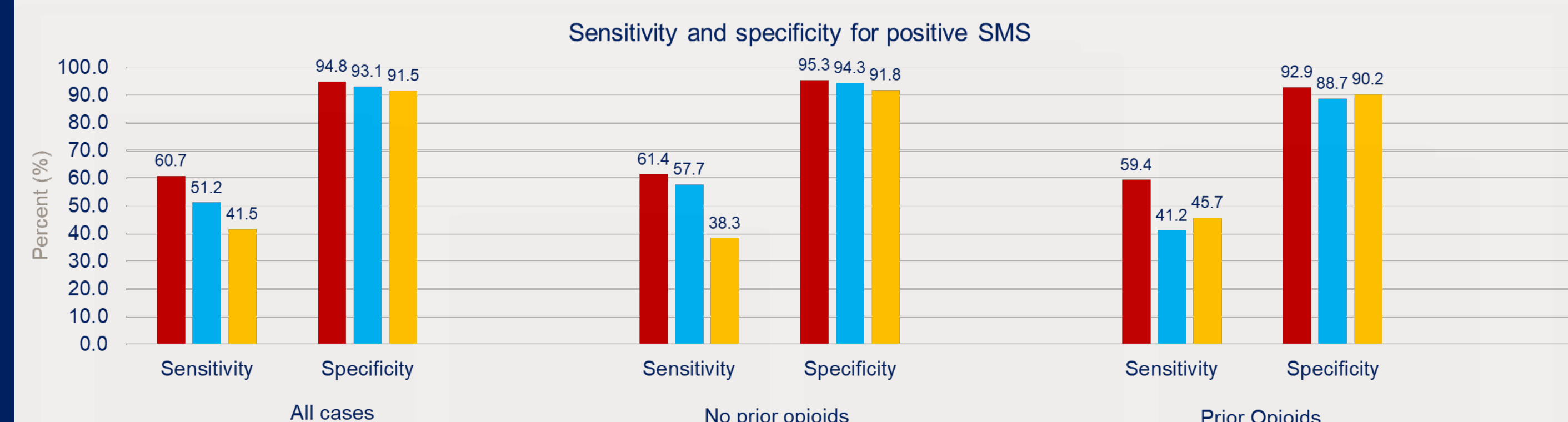


Figure 11. There is no significant differences in sensitivity and specificity among radiologic, emergency department, and pathologic diagnoses of acute cholecystitis using positive SMS. Therefore this null hypothesis is accepted.