

INITIAL EXPERIENCE OF VOLUME CT IN PEDIATRICS

Can Anesthesia Be Avoided?

Kerri Highmore^{1,2} and Elka Miller^{1,2}
¹Department of Medical Imaging, CHEO; ²University of Ottawa, Ontario, Canada

BACKGROUND & PURPOSE

- Anesthesia is commonly used in pediatric imaging due to the young age of the patient and inability for breath-hold compliance

Purpose:

- **To evaluate the use of Volume CT (vCT) scanning in the pediatric patient population as an alternative non-anesthesia imaging technique**
- Volume CT scanning is a fast CT imaging technique
 - 160 mm wide coverage with one short rotation scan
 - Can reduce the risk of patient motion due to fast scanning time (0.35 seconds)
 - Can lower radiation dose exposure by eliminating overlap required in helical scanning

MATERIALS AND METHODS

- Retrospective study, REB approved
- vCT scans performed November 2017 - September 2018 with a 320- row multidetector CT scanner
- 48 children: ≤ 3 years old and younger, no sedation
- vCT acquired exams were assessed for:
 - Presence or absence of motion artifact
 - Degree of motion artifact
 - Level of the involved in the motion artifact: Upper, mid, or lower aspect of the field of view

RESULTS

- The final study included CT exams of 48 children (23 male, 25 female; mean age 1 year 2 months; range 2 weeks old to 3 years)
- All vCT acquisition. None of the cases required sedation/anesthesia

Table 1: Anatomical Region Scanned

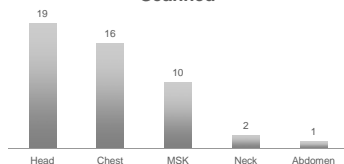


Table 2: Presence of Artifact

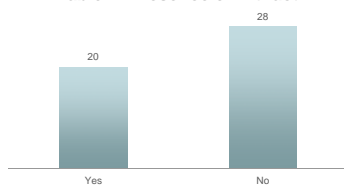


Table 3: Severity of Artifact Based on Anatomical Region

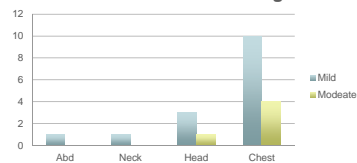
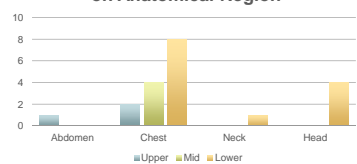


Table 4: Artifact Location Based on Anatomical Region



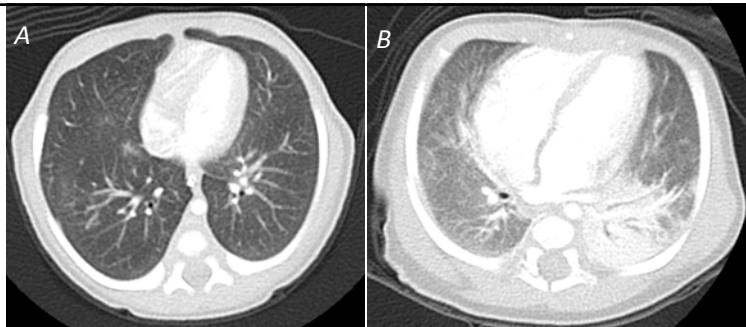


Fig A vCT Chest WO Contrast. 5 days old female. Assess for possible sequestration. Artifact graded as "mild".

Fig B vCT Chest W Contrast. 6 week old male. Hx TAPVR, R/O pulmonary embolism. Artifact graded as "moderate".

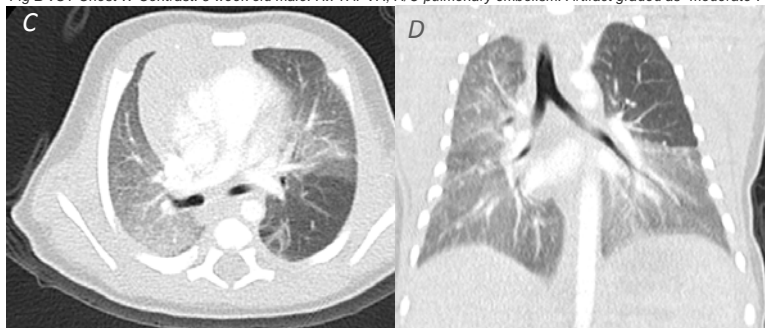


Fig. C and D vCT Chest W Contrast. 2-week-old male. Admitted for hypoxemia. Diagnosis: Congenital lobar emphysema. Artifact graded as "mild".

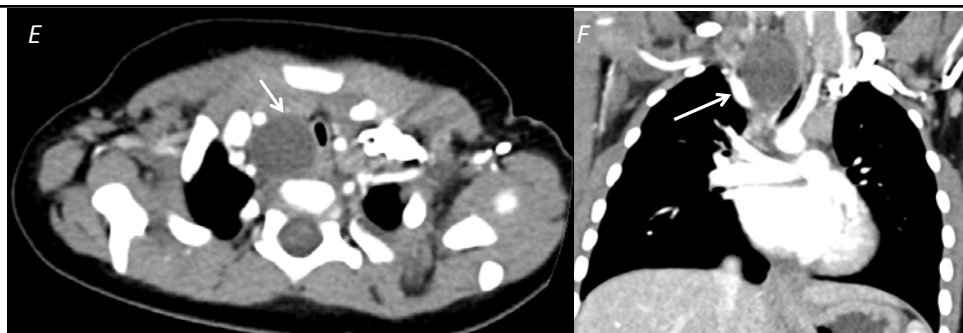


Fig. E and F vCT Chest W Contrast. 1 month old female. Assess anterior mediastinal mass. Diagnosis: Duplication cyst (arrow) with tracheal deviation. Artifact graded as "none".

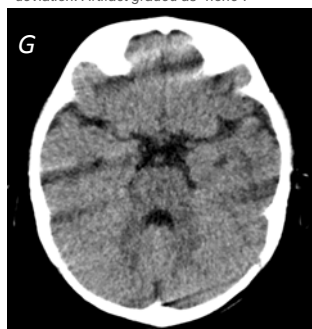


Fig. G vCT Head WO Contrast. 9 month old male. Fall 4 days ago. Artifact graded as "moderate".

Degree of motion artifact was graded as: Mild, Moderate, and Severe. None of the cases with artifact were graded as "severe"

DISCUSSION

- Motion artifact was noted on 41% of the cases. Majority mild, with only 10% with moderate artifact
- All studies were felt to be diagnostic as repeat examination with anesthesia was not required
- Chest CT had the highest percentage of artifact (88%)
 - Our cohort (< 3 years old) scans obtained at quiet breathing, no breath-holds
 - Highest percentage of artifact was at the lung bases (57%, 10/14 cases)
 - Lung apices are more resistant to motion artifact than the lung bases [7]
- vCT Head artifact had streak densities in the posterior fossa
- Although not the focus of the study, important to note vCT has the potential of radiation reduction
 - Volume CT reported to reduce the radiation dose compared to Helical CTs [6] in keeping with ALARA and Image Gently principles

LIMITATIONS

- Small (n=48) and heterogeneous sample size
- Diagnostic accuracy was not compared directly, however, studies were felt to be diagnostic as none were repeated for the same indication
- vCT is a fast imaging technique, but certain indications will likely still require breath-hold anesthesia (ie. Interstitial lung disease)

CONCLUSION

Our initial experience support the principle that Volume CT scanning in young children can avoid the need for sedation, reducing radiation exposure, and still maintaining diagnostic image quality

Larger sample size testing this technique is still required



uOttawa

CHEO

REFERENCES

1. Kelly DM, Hasegawa I, Borders R, Hatabu H, Boiselle PM. High-resolution CT using MDCT: comparison of degree of motion artifact between volumetric and axial methods. *AJR* 2004; 182:757-759
2. Studler U, Gluecker T, Gongart G, Roth J, Steinbrich W. Imaging quality from high-resolution CT of the lung: comparison of axial scans and of sections reconstructed from volumetric data acquired using MDCT. *AJR* 2005; 185:602-607
3. Schoepf UJ, Becker CR, Bruening RD, et al. Electrocardiographically gated thin-section CT of the lung. *Radiology* 1999; 212:649-654
4. Bastos, M, Lee E, Strauss K, Zurakowski D, Tracy D, Boiselle P. Motion Artifact on High-Resolution CT Images of Pediatric Patients; Comparison of Volumetric and Axial CT Methods. *AJR* 2009; 193: 1414-1418
5. Kazerooni EA. High-resolution CT of the lungs. *AJR* 2001; 177:501-519
6. Jeon SK, Choi YH, Cheon JE, Kim WS, Cho YJ, Hha JY, Lee SH, Hyun H, Kim IO. Unenhanced 320-row multidetector computed tomography of the brain in children: comparison of image quality and radiation dose among wide-volume, one-shot volume, and helical scan modes. *Ped Rad* 2018; 48:594-601
7. Kelly DM, Hasegawa I, Borders R, Hatabu H, Boiselle PM. High-resolution CT using MDCT: comparison of degree of motion artifact between volumetric and axial methods. *AJR* 2004; 182:757-759