



The Benefits and Potential Pitfalls of Lack of Oral Contrast on CT in the Emergent Setting

USC

G K Spanos, M Balouch, S Reddy, D R Radin, S Palmer, S Swadron, V A Duddalwar

Department of Radiology, University of Southern California, Los Angeles, California 90033




Introduction

CT scans are performed frequently in the ED setting to evaluate a variety of clinical scenarios. Traditionally most of these scans are performed with intravenous and oral contrast except for the evaluation of renal colic. However there is mounting evidence that oral contrast may not increase the accuracy of these studies and may actually degrade the study in a number of scenarios. 1-3

Purpose

In this study, we evaluate the benefits and pitfalls of not using oral contrast in an emergent setting. We analyze the impact of discontinuing oral contrast on patient care in the ER, taking into account the time savings and monetary savings, as well as acceptance by both radiologists as well as clinicians.



Use of Oral Contrast during CT scans: Current literature review

- Prospective study of 100 emergency department (ED) patients with abdominal pain where patients were scanned without oral contrast and then with oral contrast. Only 2 cases out of 100 were discrepant. 4
- In the case of appendicitis, a meta-analysis of 23 studies showed similar sensitivity (95% vs. 92%), specificity (97% vs. 94%) and accuracy (97% vs. 89%). Other studies showed that diagnostic confidence was not hindered. 2,6
- The ACR Appropriateness Criteria®, evidence-based guidelines formulated by expert review panels, state the following:

- In cases of right lower quadrant pain, use/ non use of oral or rectal contrast does not change accuracy of the study. 3,6,8
- Oral contrast should not be used for evaluating suspected small bowel obstruction and the IV contrast makes the biggest contribution. 2,7

Potential Benefits and Pitfalls of No Oral Contrast

Benefits:

- Saves at least 90 minutes (time to opacify bowel)
- Increases patient compliance
- Increases ER throughput, by providing results to ER more rapidly
- May increase the accuracy of study because:
 - Oral contrast may obscure masses, or hematomas²
 - Oral contrast may give a false idea of level of obstruction²

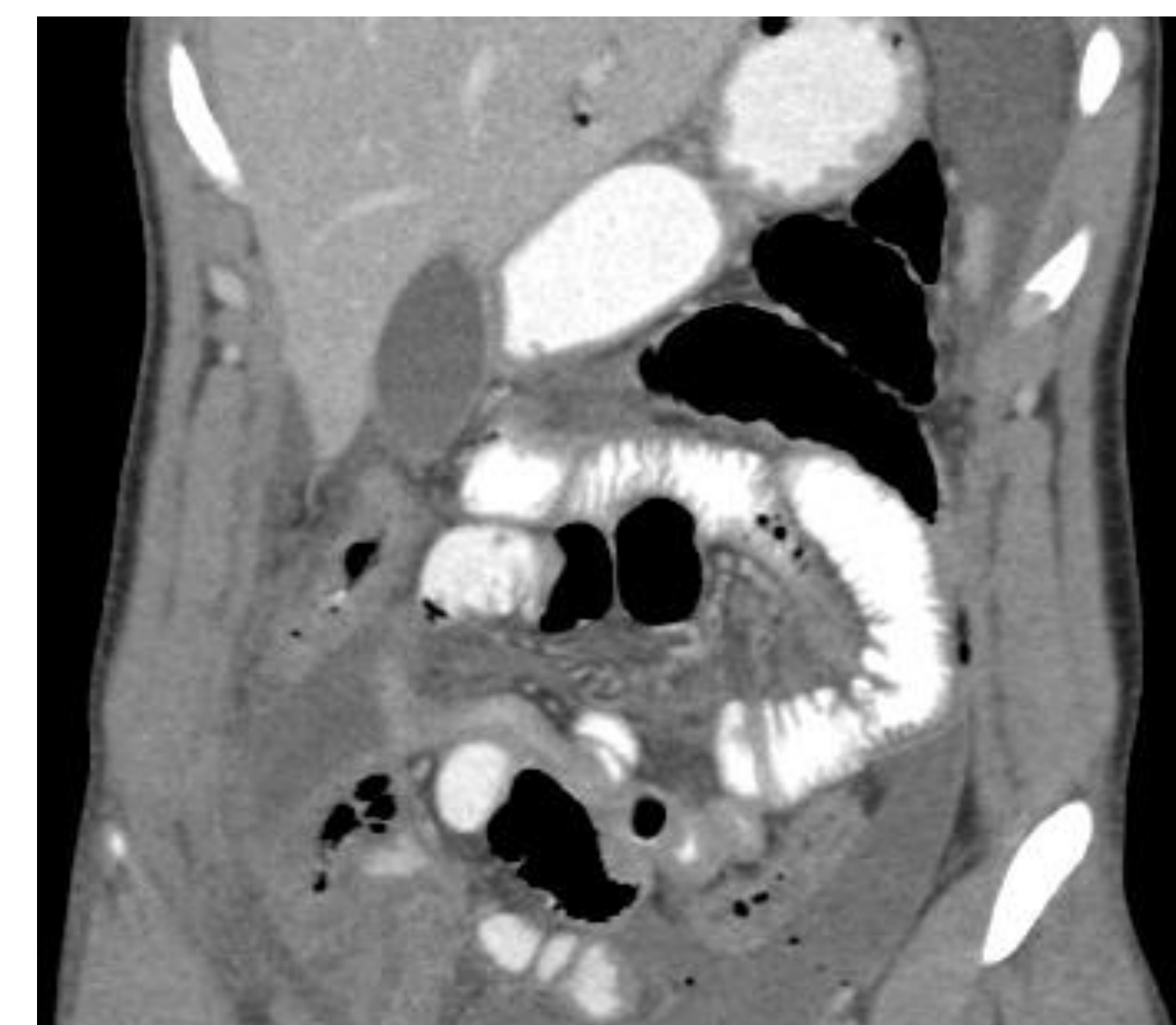
Pitfalls:

- Limited evaluation for suspected fistulas
- Limited evaluation for suspected postoperative leaks

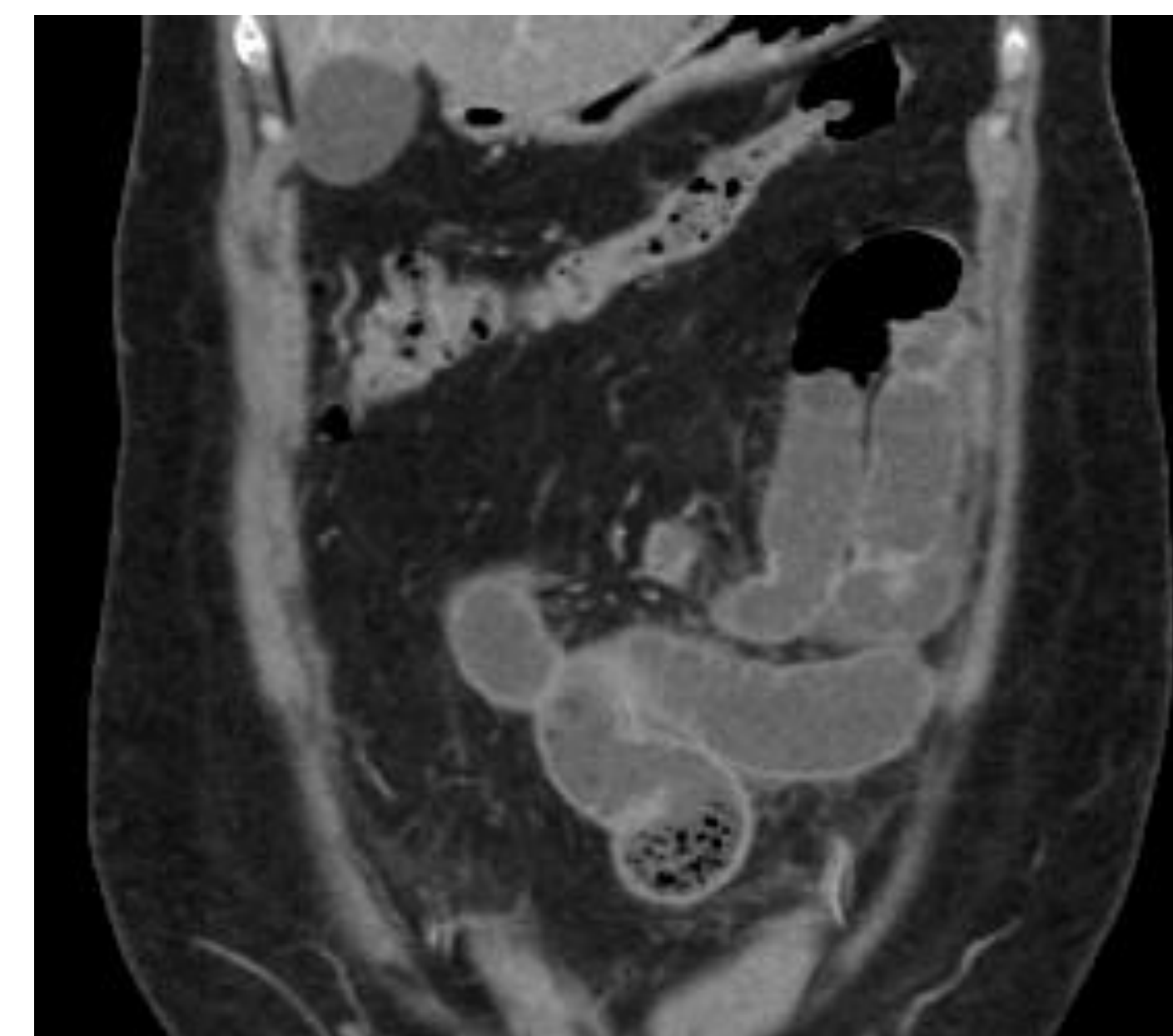
The Plan

Starting March 1st 2010, **NO ORAL CONTRAST** was used for CT scans of the abdomen and pelvis requested from the LAC + USC Emergency Department, with the exception of ruling out fistulas.

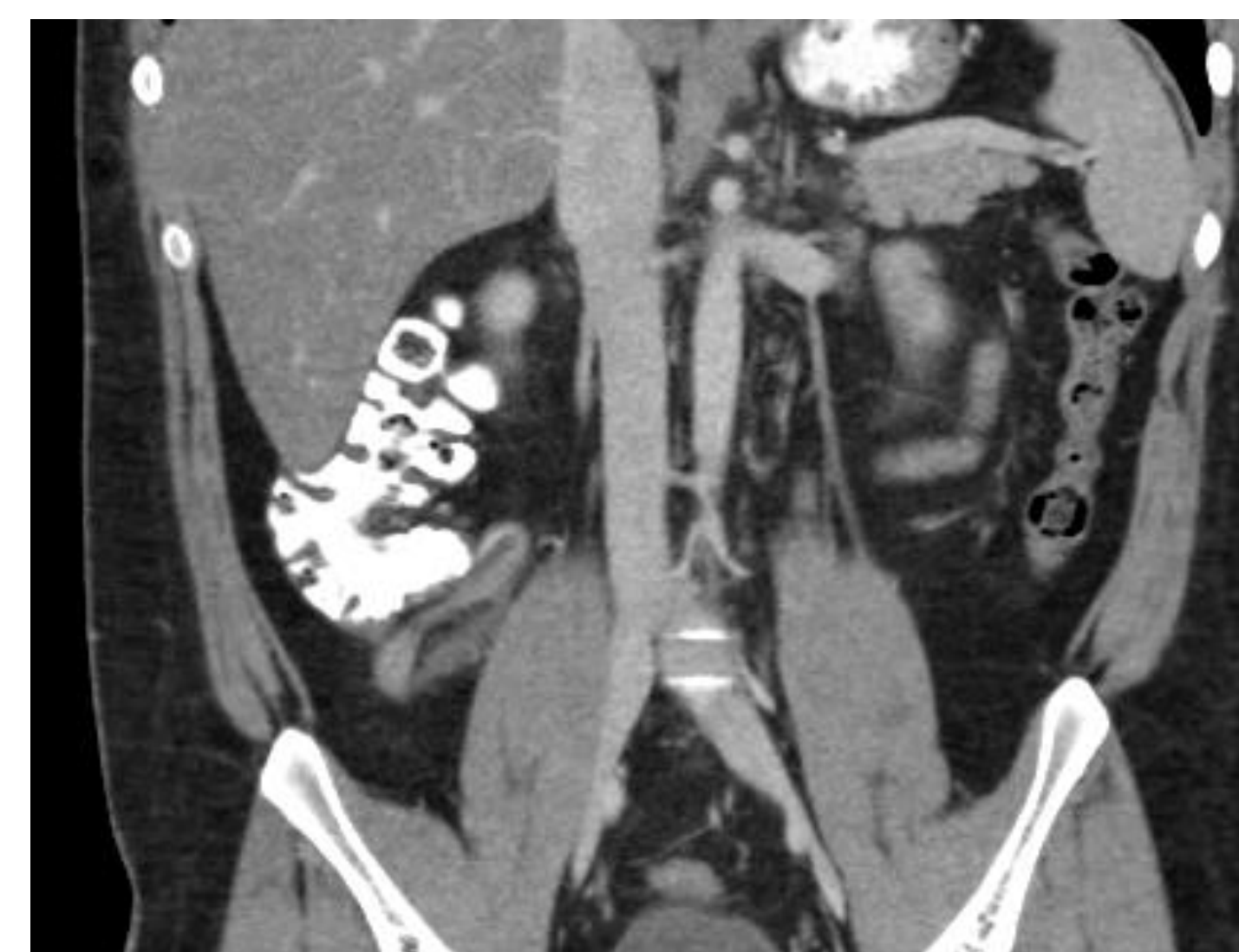
Do we really need oral contrast to make the diagnosis?



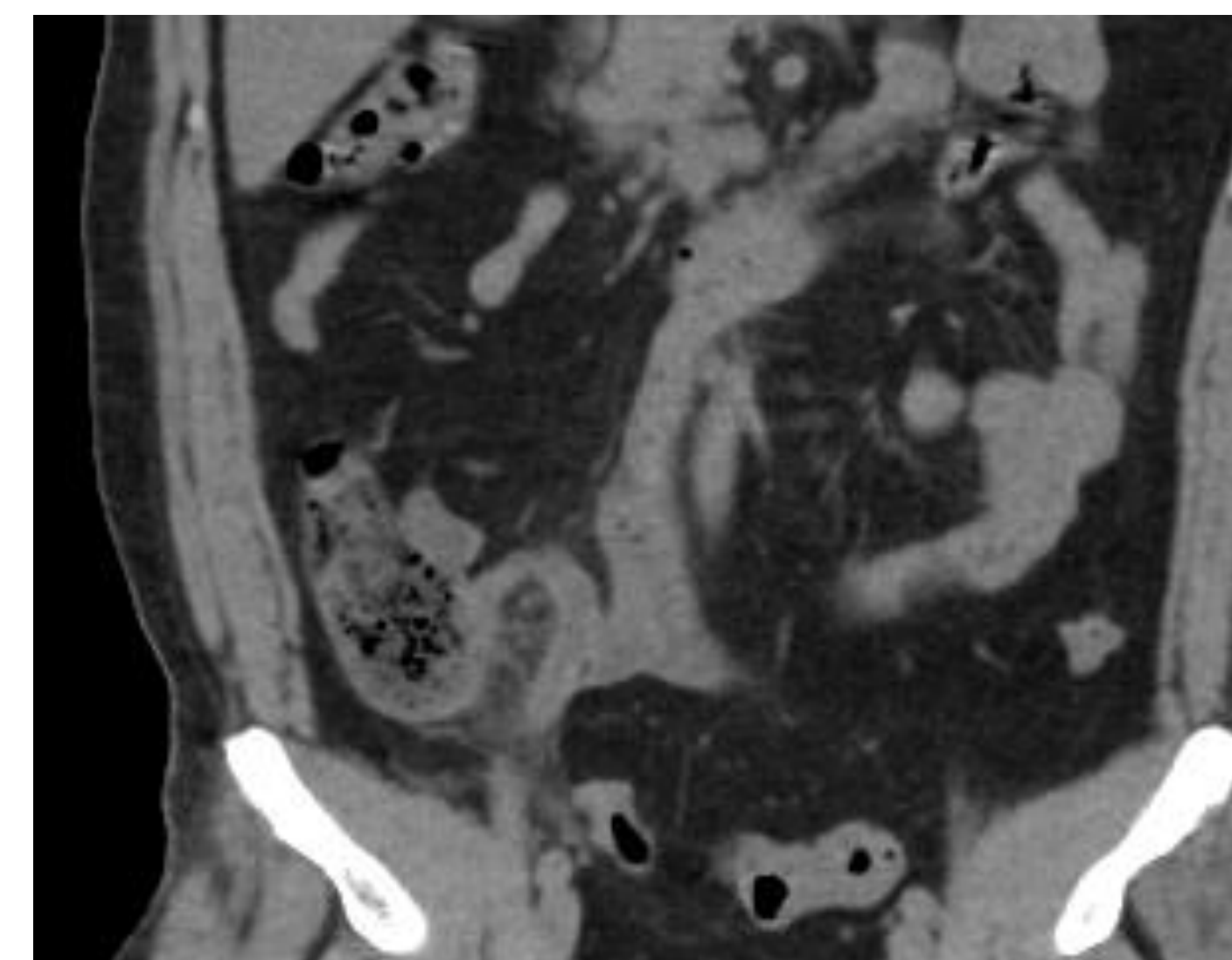
SBO with oral contrast



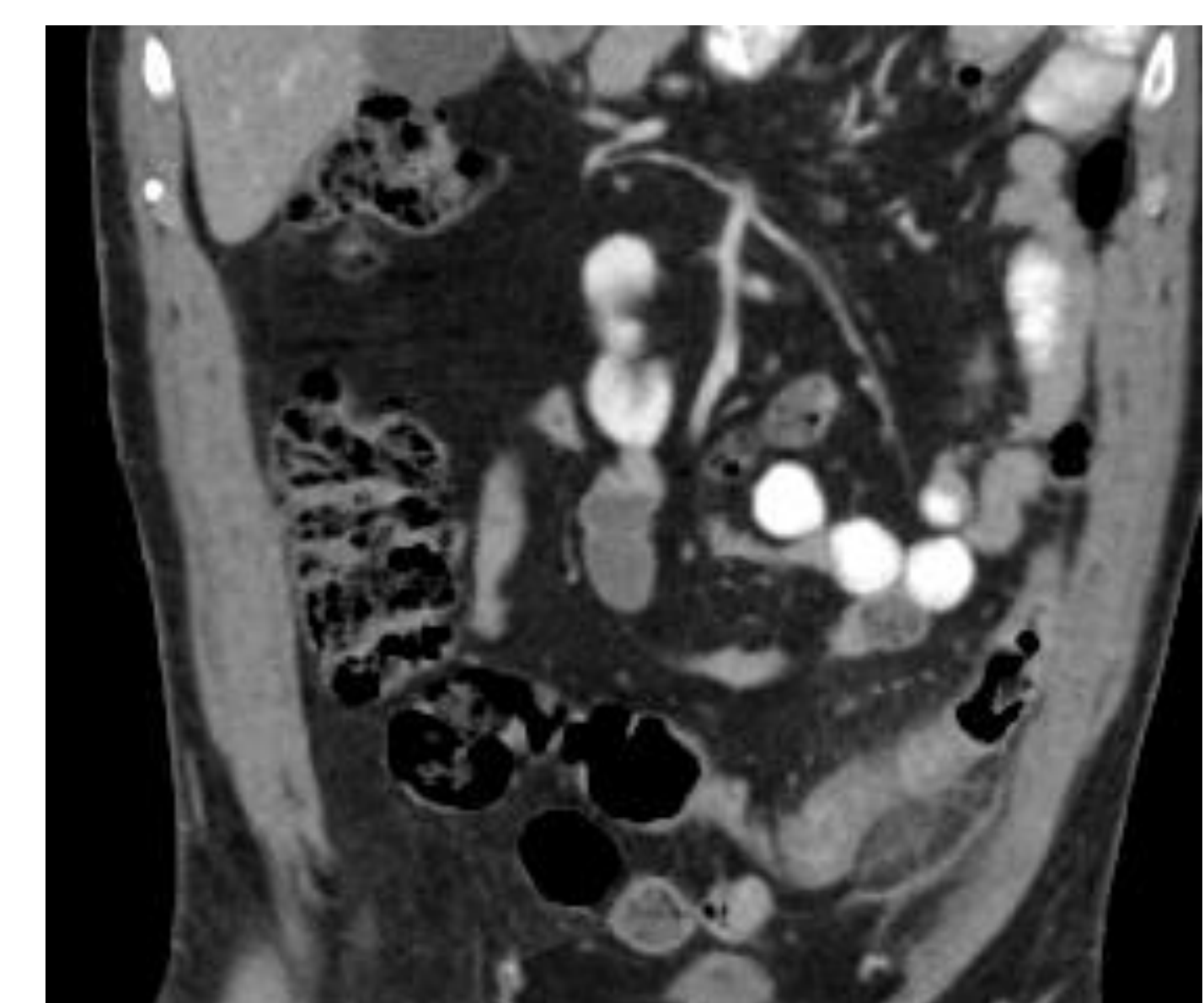
SBO without oral contrast



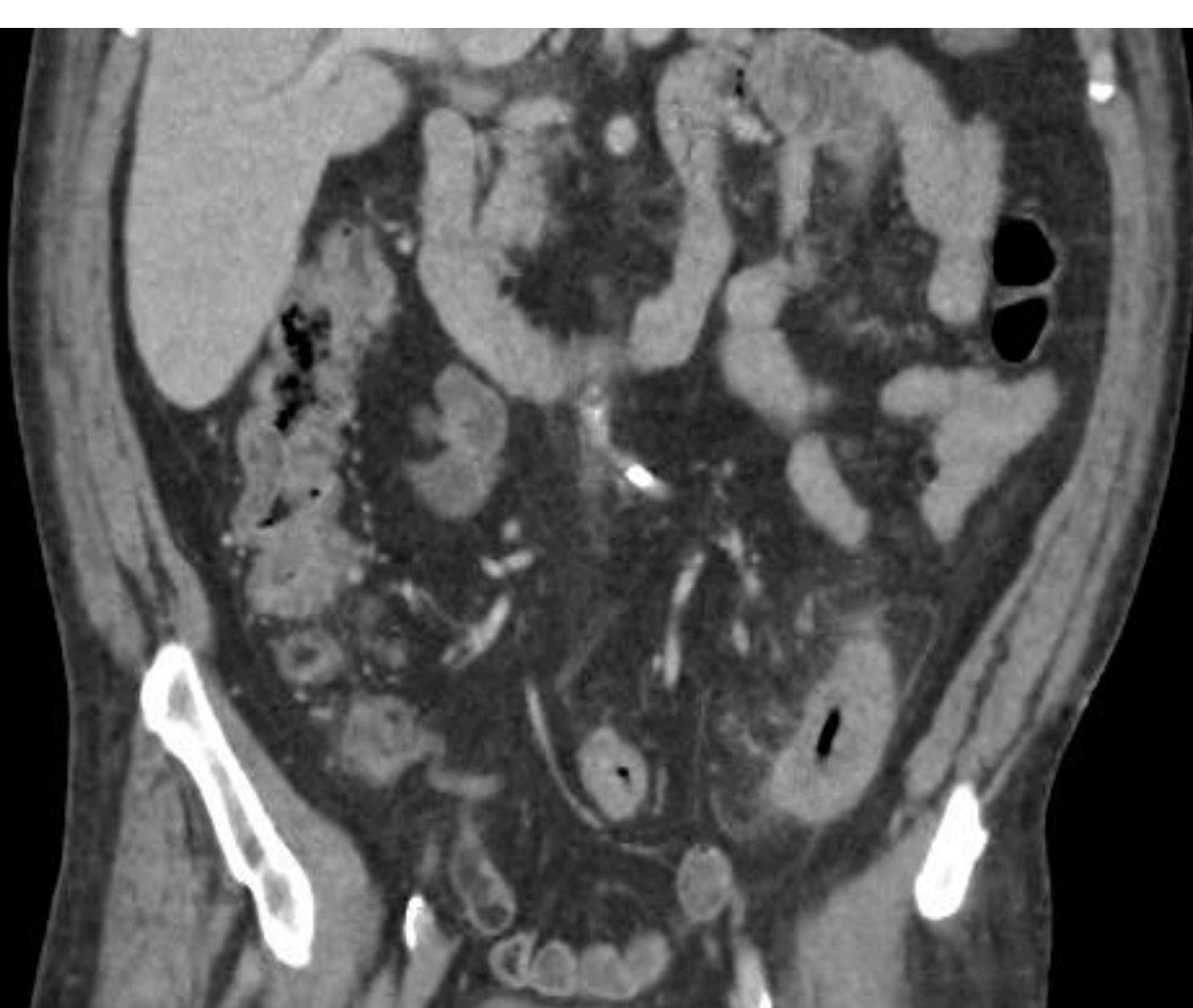Appendicitis with oral contrast



Appendicitis without oral contrast



Diverticulitis with oral contrast



Diverticulitis without oral contrast

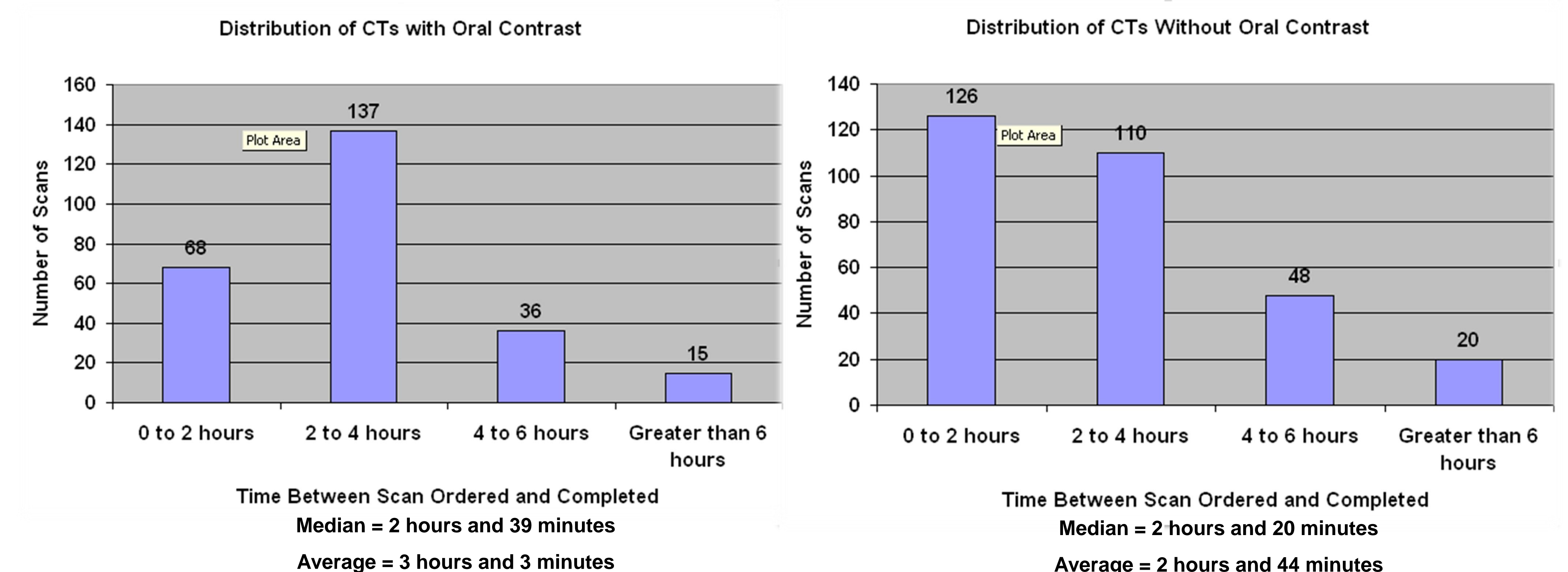
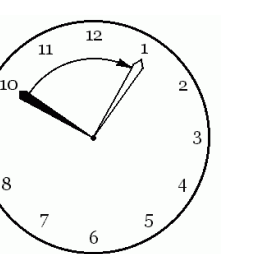
Method:

A retrospective review of data was performed after the study plan was approved by the local institutional review board.

- Data was reviewed from the Hospital and Radiology Information Systems as well as the PACS
- Data sets were:
 - Patients who had a CT scan of the abdomen/pelvis **WITH** oral contrast in the month prior to the new institutional policy (Feb. 2010).
 - Patients who had a CT scan of the abdomen/pelvis **WITHOUT** oral contrast in the month prior to the new institutional policy (Mar. 2010).
- Exclusion criteria included "trauma" and "rule-out fistula" on the initial ER requisition.
- The waiting times between the physician placing the order and the patient obtaining the scan were obtained.

Results:

- We calculated the difference between time ordered and the time the study was started on our PACS.
- There was only one case where the reading radiologist felt that oral contrast may have added to the diagnostic confidence
- In Feb 2010, when all patients received oral contrast, out of 256 patients, the average time it took was **3 hours and 3 minutes**.
- In March 2010 when patients didn't receive oral contrast, out of 304 patients, the average time was **2 hours and 44 minutes**.
- This showed a savings of **19 minutes**.



Conclusion:

- In our experience at the LAC+USC ER, not using oral contrast saved an average of 19 minutes. While more time could potentially be saved, factors such as high demand on imaging and patient transport resources limit the time saved currently.
- Performing studies without oral contrast saves about an average of \$25000-\$30000 a year just in terms of the cost of oral contrast. However cost of the time savings on the management of the patient in the ED have not been calculated.



References:

- ACR Appropriateness Criteria (2010), Acute Abdominal Pain and Fever or Suspected Abdominal Abscess. Amer. Coll. of Radiology. Retrieved November 15, 2010, from <http://acsearch.acr.org/>.
- ACR Appropriateness Criteria (2010), Suspected Small Bowel Obstruction. Amer. Coll. of Radiology. Retrieved November 15, 2010, from <http://acsearch.acr.org/>.
- ACR Appropriateness Criteria (2010), Right Lower Quadrant Pain – Suspected Appendicitis. Amer. Coll. of Radiology. Retrieved November 15, 2010, from <http://acsearch.acr.org/>.
- Lee SY, Coughlin B, Wolfe JM, Polino J, Blank FS, Smithline HA. Prospective comparison of helical CT of the abdomen and pelvis without and with oral contrast in assessing acute abdominal pain in adult emergency department patients. Emerg Radiol. 2006;12:150-157. Epub 2006 Apr 21.
- Anderson BA, Salem L, Flum DR. A systematic review of whether oral contrast is necessary for the computed tomography diagnosis of appendicitis in adults. Am J Surg. 2005;190:474-478.
- Anderson SW, Soto JA, Lucey BC, et al. Abdominal 64-MDCT for suspected appendicitis: the use of oral and IV contrast material versus IV contrast material only. AJR 2009;193:1282-1288
- Megibow AJ, Balthazar EJ, Cho KC, Medwid SW, Birnbaum BA, Noz ME. Bowel obstruction: evaluation with CT. Radiology 1991; 180(2):313-318.
- Maglinte D, Herlinger H, Turner W, Kelvin F. Radiologic management of small bowel obstruction: a practical approach. Emerg Radiol 1994; 1994(1):138-149.